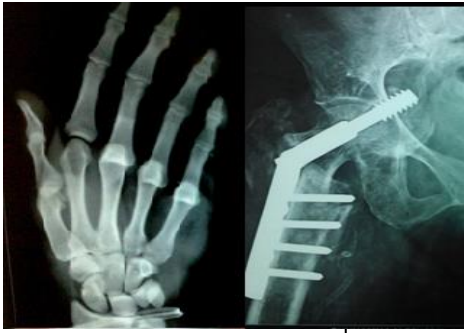

International Journal of Orthopaedics Sciences

E-ISSN: 2395-1958
P-ISSN: 2706-6630
IJOS 2023; 9(3): 268-272
© 2023 IJOS
<https://www.orthopaper.com>
Received: 22-05-2023
Accepted: 21-06-2023

Dr. Nitheesh Sekar
Department of Orthopaedics
Saveetha Medical College and
Hospital, Thandalam, Chennai,
Tamil Nadu, India

Dr. Raja Sujith Kumar
Department of Orthopaedics
Saveetha Medical College and
Hospital, Thandalam, Chennai,
Tamil Nadu, India

Dr. Meenakshi Rakesh
Department of Orthopaedics
Saveetha Medical College and
Hospital, Thandalam, Chennai,
Tamil Nadu, India

Dr. Arjun Krishnan
Department of Orthopaedics
Saveetha Medical College and
Hospital, Thandalam, Chennai,
Tamil Nadu, India

Dr. Yeshwanth Subash
D.N.B (Ortho), M.N.A.M.S
Department of Orthopaedics
Saveetha Medical College and
Hospital, Chennai, Tamil Nadu,
India

Corresponding Author:
Dr. Yeshwanth Subash
D.N.B (Ortho), M.N.A.M.S
Department of Orthopaedics
Saveetha Medical College and
Hospital, Chennai, Tamil Nadu,
India

Comparing the corticosteroid injection and A1 pulley percutaneous release in treatment of trigger finger: A clinical trial

Dr. Nitheesh Sekar, Dr. Raja Sujith Kumar, Dr. Meenakshi Rakesh, Dr. Arjun Krishnan, Dr. Yeshwanth Subash

DOI: <https://doi.org/10.22271/ortho.2023.v9.i3d.3435>

Abstract

Background: There are several treatment options, ranging from conservative therapy to surgical release, for trigger finger, a prevalent condition in rheumatologic practice that results in a triggering or locking that may provide an uncomfortable sensation. The study's goal was to examine the functional results of percutaneous A1 pulley release and corticosteroid injection administration in the treatment of trigger finger patients.

Methods: This is a prospective study of 30 patients with Trigger Finger conducted between May 2021 to May 2022 with a follow up of 2 years

Results: There were 12 female and 18 male participants in our study, and the right side was the side that was most frequently afflicted. The patient was between the ages of 29 and 59, with a mean of 43. All patients who underwent percutaneous trigger finger release were able to flex and extend their fingers without any pain at the end of six months, returning them to their pre-injury state. The average VAS score after injection was 3. The Quinell score 4 drastically decreased from a post- injection mean of 3. The average VAS score after surgery was 2. After surgery, the Quinell score 3 drastically decreased from a mean of 1. Every patient was pleased with the procedure and the functional outcomes.

Conclusion: When compared to intraarticular steroid injection, percutaneous trigger finger release is a viable choice for treating trigger finger.

Keywords: PTFR, trigger finger, corticosteroid injection, quinnel score

Introduction

The disorder known as trigger finger develops when the osteofibrous canal of the A1 pulley blocks the flexor tendon's ability to glide freely, resulting in painful triggering or clicking movements [1]. The most frequent cause is overuse injury to the hands from gripping with increasing pull on the flexor tendons. A secondary proximal interphalangeal flexion contracture develops as a result of a patient's tendency to avoid a painful trigger finger over time. Incidence of trigger finger is 2-3%, with a potential 10% increase among diabetics [2]. The dominant side is most frequently affected, and the middle and index fingers are the most frequently implicated digits. This condition is more frequently seen in females [3]. Right hand to left hand ratio is 3:2, whereas women outnumber men six to one [4]. The severity of trigger fingers is rated using Quinell's classification which is the one that is frequently used [5]. The pathological mismatch between the retinacular sheath's volume and its contents, which prevents the tendon from smoothly passing through the A1 pulley, is the pathogenesis of trigger finger. Upon examination, a fibrous tissue lump can be felt in the palm, close to the volar side's metacarpal-phalangeal joint (MCP). Volar tenosynovitis may be a symptom of an inflammatory disorder such rheumatoid arthritis, psoriatic arthritis, or apatite crystal deposition disease [5]. The purpose of treatment is to restore the affected digit's natural, full range of motion. There have been many proposed therapy approaches, hence both conservative and surgical modes of treatment have been included. Thus, the conservative course of treatment entails the use of ice packs, splinting, non-steroidal anti-inflammatory drugs (NSAIDS), and corticosteroid injection.

It is assumed that conservative treatment is effective in 85% of trigger finger cases. If non-operative treatment is unsuccessful, surgical release is advised. Conversely, open or percutaneous release of the A1 pulley is part of the surgical procedure. Thus, corticosteroid injections were administered near the flexor sheath. In terms of triggering and tenderness relief, the effectiveness of corticosteroid injection is believed to be between 70 and 80 percent. In a one-year perspective, the recurrence rate is substantial, reaching 33% [6]. Drainage and medicines are needed for infection of the hand's tendon sheaths. Drug addicts and those with diabetes may be more susceptible to contracting such diseases. 90% efficacy makes surgical management more efficient. Additionally, a reported 3-9% recurrence rate and a 0-5% complication rate. In 1958, Lorthier was the first to describe how to release the trigger finger percutaneously while using a fine tenotome [7]. Then, other percutaneous procedures with positive outcomes and few side effects have been recorded, using a variety of tools and techniques. Over the past two decades, the technique of percutaneous release surgery has grown widespread. Infection, bowstringing, or damage to the digital nerve were not recorded as problems in Trowski, *et al.* 97% full resolution of triggering report [8]. Consequently, the study's goal is to examine the functional results of percutaneous A1 pulley release and corticosteroid injection administration in the treatment of trigger finger patients.

Materials and Methods

This was a prospective cohort study conducted at Department of Orthopedics Saveetha Medical College and Hospital in Thandalam from May 1, 2022, through May 31, 2024. Thus, 30 trigger finger patients were chosen for the study, out of whom 15 received injections of corticosteroids while the remaining 15 received percutaneous trigger finger release. Patients were chosen based on whether they would receive injections of corticosteroids or percutaneous trigger finger release, with odd numbers receiving the injections and even numbers receiving the percutaneous trigger finger release. Patients who had symptoms that were worse than Quinells grade 2 and who had never had a local injection or surgical release were included. Other requirements included patient consent to therapy and consent to routine follow-up. Trigger fingers of grade 1 and any post-traumatic or post-inflammatory arthritic fingers were excluded, as well as individuals who were unwilling to get therapy or follow up. In the OPD, the same surgeon performed each procedure. Every patient was seen in the outpatient department and told to go to the hospital. An extensive history was collected, including details about the patient's injury and when they were admitted to the hospital. Information regarding any prior treatments was then retrieved, and a physical examination was then carried out. The affected limb was then given a local examination, and findings included a deformity over the hand area, a restriction in the range of motion at the digit involved, tenderness at the level of the A1 Pulley, a palpable nodule present at the flexor tendon, fixed flexion of the PIP joint, and triggering with digit flexion and extension. Provocative testing - flexion and extension of the digit may replicate symptoms - was observed and recorded. Povidone-iodine solution should be used to sterilize the area. Draw up a solution of 1 mL of lidocaine and 1 mL of corticosteroid (triamcinolone 40mg/ml) using a 16- or 18-gauge needle

connected to a 5-mL syringe. A 25-gauge needle should then be used. By passing the needle through the finger's flexion crease at the base of the finger, in the middle of the finger, at an angle of around 50 degrees, the needle should be positioned. In order to reach the bone, let the needle pass through both flexor tendons. When the resistance the needle faces lessens, the needle has entered the flexor sheath. Continue to slowly withdraw the needle while applying forward pressure to the syringe's barrel. The solution ought to be injected into the flexor sheath without needing to use any force, and it ought to do so relatively simply. Apply povidone-iodine solution to the area to sterilize it. 1ml of localized lidocaine infiltration was carried out. An appropriate depth is reached by inserting an 18-gauge hypodermic needle at the level of the A1 pulley (skin fold of the metacarpal joint). The sheath around the flexor tendon was severed by moving the needle longitudinally and parallelly. Following the division of the A1 pulley, we carried out a compression-confirming test (CCT) to identify any incomplete release sites by pressing at the A1 pulley while telling the patients to flex and extend their affected fingers. We could tell that the A1 pulley was entirely separated if the flexor moved smoothly. Evaluation of the outcomes was done over the follow-up periods of three weeks, six weeks, and six months to see how the level of triggering, swelling, pain, and patient satisfaction changed the Quinells grade [Table-1] was calculated using the VAS score [Figure-1]. Furthermore, stiffness, scarring, and paresthesia-related complications were assessed. The data analysis tool of choice was SPSS version 17. A P-value of 0.05 or less was required to be considered statistically significant.

Table 1: Quinell grading of trigger finger

Grade	Clinical Findings during flexion and extension
0	Normal Movement
1	Uneven Movement
2	Actively correctable
3	Passively correctable
4	Fixed deformity

Table 2: Demographic characteristics of patients with trigger finger and treatment groups

S. No	Variable	Steroid Injection	Percutaneous Trigger Finger Release
1.	Number of patients (N=30)	15	15
2.	Digits involved	Ring finger	Ring finger
3.	Mean age in years	43	43
4.	Gender-Male/Female	Males	Males
5.	Mean duration of the disease	5 Months	5 months
6.	Hand involved-Right/Left	Right	Right

Table 3: Complications noted during the postoperative follow-up period

S. No	Complications	Total no of Patients (N=30)
1.	Stiffness of digits	4
2.	Scarring	2
3.	Paraesthesia	0
4.	Normal	24

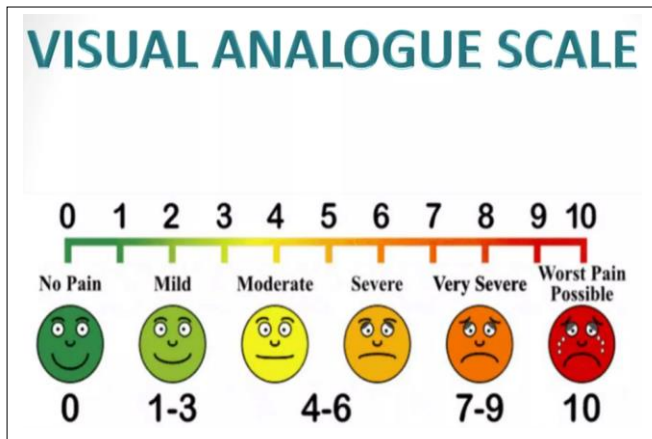


Fig 1: VAS Scale

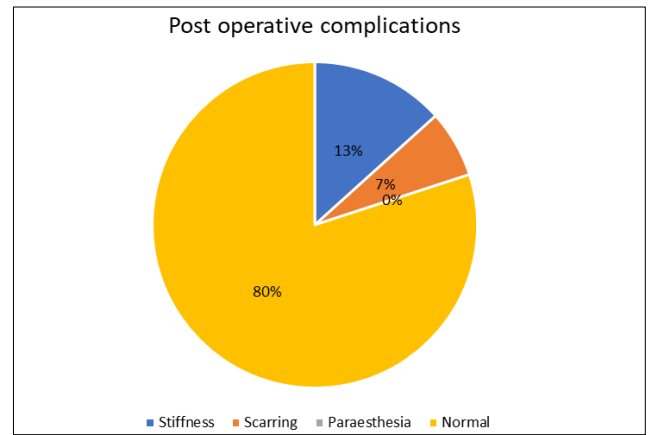


Fig 2: Postoperative complications which were encountered during the follow up period

MASTER CHART

S.NO	AGE/SEX	SIDE	SITE (FINGER INVOLVED)	DURATION (IN MONTHS)	MODE OF TREATMENT (CI VS PTFR)	PRE OP VAS SCORE	PRE OP QUINNEL SCORING	POST OP VAS SCORING			POST OP QUINNEL SCORING			COMPLICATIONS (PARASTHESIA, SCARRING, STIFFNESS)
								3 WEEKS POST OP VAS SCORING FOR CORTICOSTEROID INJECTION (CI) AND PERCUTANEOUS TRIGGER FINGER RELEASE (PTFR)	6 WEEKS POST OP VAS SCORING FOR CORTICOSTEROID INJECTION (CI) AND PERCUTANEOUS TRIGGER FINGER RELEASE (PTFR)	6 MONTHS POST OP VAS SCORING FOR PERCUTANEOUS TRIGGER FINGER RELEASE (CI) AND PERCUTANEOUS TRIGGER FINGER RELEASE (PTFR)	3 WEEKS POST OP QUINNEL SCORING FOR CORTICOSTEROID INJECTION (CI) AND PERCUTANEOUS TRIGGER FINGER RELEASE (PTFR)	6 WEEKS POST OP QUINNEL SCORING FOR PERCUTANEOUS TRIGGER FINGER RELEASE (CI) AND PERCUTANEOUS TRIGGER FINGER RELEASE (PTFR)	6 MONTHS POST OP QUINNEL SCORING FOR PERCUTANEOUS TRIGGER FINGER RELEASE (CI) AND PERCUTANEOUS TRIGGER FINGER RELEASE (PTFR)	
1)	30/M	RIGHT	RING	3	CI	6/10	3	CI-4/10	CI-4/10	CI-3/10	CI-2	CI-2	CI-2	STIFFNESS
2)	37/M	RIGHT	MIDDLE	3	PTFR	5/10	4	PTFR-5/10	PTFR-3/10	PTFR-2/10	PTFR-3	PTFR-2	PTFR-1	SCARRING
3)	42/M	LEFT	INDEX	4	CI	6/10	4	CI-4/10	CI-4/10	CI-3/10	CI-3	CI-3	CI-3	NIL
4)	49/M	RIGHT	MIDDLE	7	PTFR	6/10	3	PTFR-5/10	PTFR-3/10	PTFR-2/10	PTFR-2	PTFR-2	PTFR-1	NIL
5)	54/F	LEFT	RING	6	CI	5/10	4	CI-4/10	CI-4/10	CI-3/10	CI-3	CI-3	CI-3	STIFFNESS
6)	58/F	RIGHT	MIDDLE	5	PTFR	7/10	3	PTFR-5/10	PTFR-3/10	PTFR-2/10	PTFR-2	PTFR-2	PTFR-1	NIL
7)	36/M	LEFT	INDEX	2	CI	6/10	3	CI-4/10	CI-4/10	CI-3/10	CI-2	CI-2	CI-2	NIL
8)	44/F	LEFT	MIDDLE	4	PTFR	6/10	4	PTFR-5/10	PTFR-3/10	PTFR-2/10	PTFR-3	PTFR-2	PTFR-1	SCARRING
9)	51/F	RIGHT	INDEX	5	CI	5/10	3	CI-4/10	CI-4/10	CI-3/10	CI-2	CI-2	CI-2	STIFFNESS
10)	30/F	RIGHT	INDEX	3	PTFR	6/10	3	PTFR-5/10	PTFR-3/10	PTFR-2/10	PTFR-2	PTFR-2	PTFR-1	NIL
11)	32/F	LEFT	RING	6	CI	6/10	3	CI-4/10	CI-4/10	CI-3/10	CI-3	CI-3	CI-3	NIL
12)	41/F	LEFT	INDEX	7	PTFR	6/10	4	PTFR-5/10	PTFR-3/10	PTFR-2/10	PTFR-3	PTFR-2	PTFR-1	NIL
13)	44/M	LEFT	RING	5	CI	6/10	3	CI-4/10	CI-4/10	CI-3/10	CI-3	CI-3	CI-3	STIFFNESS
14)	56/M	RIGHT	LITTLE	4	PTFR	5/10	4	PTFR-5/10	PTFR-3/10	PTFR-2/10	PTFR-3	PTFR-2	PTFR-1	NIL
15)	55/M	RIGHT	MIDDLE	8	CI	7/10	4	CI-4/10	CI-4/10	CI-3/10	CI-3	CI-3	CI-3	NIL
16)	29/M	RIGHT	INDEX	6	PTFR	6/10	4	PTFR-5/10	PTFR-3/10	PTFR-2/10	PTFR-3	PTFR-2	PTFR-1	NIL
17)	39/M	RIGHT	LITTLE	5	CI	6/10	3	CI-4/10	CI-4/10	CI-3/10	CI-3	CI-3	CI-3	NIL
18)	47/F	LEFT	RING	4	PTFR	6/10	4	PTFR-5/10	PTFR-3/10	PTFR-2/10	PTFR-3	PTFR-2	PTFR-1	NIL
19)	48/F	LEFT	RING	7	CI	5/10	4	CI-4/10	CI-4/10	CI-3/10	CI-3	CI-3	CI-3	NIL
20)	59/F	RIGHT	LITTLE	6	PTFR	7/10	4	PTFR-5/10	PTFR-3/10	PTFR-3/10	PTFR-3	PTFR-2	PTFR-1	NIL
21)	51/M	RIGHT	RING	3	CI	7/10	3	CI-4/10	CI-4/10	CI-3/10	CI-3	CI-3	CI-3	NIL
22)	48/M	RIGHT	LITTLE	4	PTFR	5/10	3	PTFR-5/10	PTFR-3/10	PTFR-2/10	PTFR-3	PTFR-2	PTFR-1	NIL
23)	47/M	LEFT	MIDDLE	7	CI	6/10	4	CI-4/10	CI-4/10	CI-3/10	CI-3	CI-3	CI-3	NIL
24)	44/F	RIGHT	LITTLE	8	PTFR	5/10	3	PTFR-5/10	PTFR-3/10	PTFR-2/10	PTFR-2	PTFR-2	PTFR-2	NIL
25)	40/F	LEFT	RING	5	CI	5/10	4	CI-4/10	CI-4/10	CI-3/10	CI-3	CI-3	CI-3	NIL
26)	34/M	RIGHT	RING	4	PTFR	5/10	3	PTFR-5/10	PTFR-3/10	PTFR-3/10	PTFR-2	PTFR-2	PTFR-2	NIL
27)	43/M	RIGHT	LITTLE	6	CI	7/10	4	CI-4/10	CI-4/10	CI-3/10	CI-3	CI-3	CI-3	NIL
28)	40/M	LEFT	MIDDLE	6	PTFR	6/10	4	PTFR-5/10	PTFR-3/10	PTFR-3/10	PTFR-3	PTFR-2	PTFR-1	NIL
29)	30/M	RIGHT	RING	4	CI	5/10	4	CI-4/10	CI-4/10	CI-3/10	CI-3	CI-3	CI-3	NIL
30)	39/M	LEFT	RING	6	PTFR	6/10	3	PTFR-5/10	PTFR-3/10	PTFR-2/10	PTFR-2	PTFR-2	PTFR-2	NIL

Fig 3: Show Master Chart

Results

30 patients with trigger finger received percutaneous trigger finger release and corticosteroid injection between May 2021 and May 2022. 15 of the patients underwent percutaneous trigger finger release, and 15 underwent injections of corticosteroids. Twelve female and eighteen male participants participated in our study, with 17 of the patients more frequently experiencing right-sided impairment. The patient's age ranged from 29 to 59 years, with a mean of 43. The ring finger is the one that is most frequently impacted. The average interval between the onset of symptoms and hospital admission was 5 months, ranging from 2 to 8 months [Table-2]. Prior to surgery, the trigger finger patients' preoperative VAS scores were calculated. The average score was 6, with a

range of 5 to 7. Trigger finger patients' pre-operative Quinnel's grading were averaged out, coming out at 3, with a range of 3 to 4. After the procedure, with the release of the trigger finger through the skin, there was a noticeable improvement in both the VAS score and the Quinnel score, with an average VAS score of 2 and an average Quinnel grade of 1, respectively. In contrast to corticosteroid injection, which has an average VAS score of 3 and a range of 3 to 4, average Quinnel's Grade of 3, with a range of 2 to 3. Four patients experienced postoperative stiffness around the afflicted digit, which is more frequently reported in patients who have had corticosteroid injections and have since been adequately treated with analgesics and physical therapy. However, after having their trigger fingers released by a

procedure called percutaneous trigger finger release, two patients experienced scarring over the treated digit. For these patients, a dermatologist's opinion was sought, and they received conservative treatment from drugs and scar creams [Table-3], [Figure-2]. None of the patients were lost to follow up.

Discussion

When the flexor tendon's ability to glide freely is blocked by the osteofibrous canal of the A1 pulley, trigger finger forms. According to studies conducted by Moore^[9] and Bunnel^[10] more commonly affected digit was the middle finger followed by the thumb finger whereas in our study there were patients who presented with ring finger being most commonly affected followed by middle finger. This causes painful triggering or clicking movements. Acute trigger finger could be treated conservatively with analgesics, ice pack application, orthosis during night time^[11]. Thus, percutaneous trigger finger release and corticosteroid injection are the preferred treatments. Therefore, Quinell's score and the VAS were used to evaluate the treatment's effectiveness. In our study, every patient arrived at the OPD or emergency room complaining of pain over the head of the metacarpal on the palmar side and being unable to fully flex the affected digit, which causes the patient to hear a clicking sound upon full flexion. Corticosteroid injections and percutaneous trigger finger release were used to treat the patients. The area should be sterilized with a povidone-iodine solution. A 16- or 18-gauge needle linked to a 5-mL syringe should be used to draw up a solution containing 1 mL of lidocaine and 1 mL of triamcinolone (40 mg/ml), a corticosteroid. The next step is to use a 25-gauge needle. The needle should be positioned by inserting it at an angle of around 50 degrees into the finger's flexion crease at the base of the finger, in the center of the finger. Let the needle go through the two flexor tendons to the bone. The needle has reached the flexor sheath when there is less resistance it must overcome. Apply forward pressure to the syringe's barrel while you gently continue to withdraw the needle. The first method for trigger finger percutaneous release using a tenotome was published by Lorthoir in 1958^[7]. Since then, several techniques employing a hypodermic needle, blade, or specifically made knives have been mentioned in the literature. Hypoesthesia, inadequate excision of the A1 pulley, scar tissue formation, severe tenosynovitis, tendon weakening, or even lacerations are the most frequently observed complications because it is a blind treatment.

The preoperative VAS ratings for the trigger finger patient were determined before surgery. Between 5 and 7, the range of scores was, on average, 6. Pre-operative Quinell's gradings of trigger finger patients were averaged, and the result was 3, with a range of 3 to 4. There was a considerable improvement in the VAS score and the Quinell score following the procedure, with an average VAS score of 2 and an average Quinell grade of 1, respectively. Contrarily, corticosteroid injection has an average VAS score of 3 and a range of 3 to 4, whereas the average Quinell's Grade is 3 and a range of 2 to 3. At the end of six months, all patients had recovered to their preinjury condition and were pain-free and able to perform their daily tasks. Four patients had finger stiffness, and two had scarring; these patients were treated with analgesics, physical therapy, consultation with a dermatologist, and scar creams as conservative measures. In our trial, no significant additional issues arose, and no patients were lost to follow-up. All of our patients were pleased with the procedure's

functional results. The advantages of using steroids more than once have not been extensively studied in the past. A cost-effective alternative to surgical release is to first consider two steroid injections^[12-16]. In a study comparing steroid injection with physiotherapy, Salim N *et al.* came to the statistically significant conclusion that patients receiving steroid had a success rate of 97.4% compared to 68.6%^[17]. According to a study conducted by Rhoades *et al.*^[18] the presence of 4 months of symptoms prior to the treatment correlates with poor response to intervention, According to Newport *et al.*^[19] patients who had symptoms more for more than 6 months were more likely to require surgery. As we tried to find out the correlation between duration of symptoms prior to treatment with response to treatment there was no significant relationship between the two variables which existed in the study population. The success rate for percutaneous release has been reported to be 84% - 100% at mid-term follow-up, according to a study by Jia-Guo Zhao *et al.*^[20]. The majority of the study that compares favorably with the findings of our investigation has also been examined by us. In light of the foregoing, we conclude that percutaneous trigger finger release is a viable alternative for treating trigger finger when complications are at a minimum. This results in an excellent functional outcome and enables the patient to quickly get back to his regular activities.

Conclusion

When compared to intra articular steroid injection, percutaneous trigger finger release is a viable choice for treating trigger finger

Declarations

Funding: None

Conflict of Interest: The authors declare that they have no known competing financial interests or personal relationships that could have appeared to influence the work reported in this paper.

Ethical Approval: Not required

References

1. Sato ES, Gomes Dos Santos JB, Belloti JC, *et al.* Treatment of trigger finger: Randomized clinical trial comparing the methods of corticosteroid injection, percutaneous release and open surgery. *Rheumatol.* 2012;51:93-99.
2. Fleisch SB, Spindler KP, Lee DH. Corticosteroid injections in the treatment of trigger finger: A level A and level II systematic review. *J Am Acad Orthop Surg.* 2007;15:166-171
3. Makkouk AH, Oetgen ME, Swigart CR *et al.* Trigger finger: Etiology, evaluation, and treatment. *Curr Rev Musculoskeletal Med.* 2008;1:92-96
4. Putra AANB, Kesuma AANR. Trigger finger management, comparison of conservative and surgical treatment approach in hospital decision making: A case report. *Intisari Sains Medis.* 2019;10(1):105-107. DOI: 10.1556/ism.v10i1.316
5. Aref HA, Fatemeh S, Hosein KM. Comparison between corticosteroid injection and surgery in the treatment of trigger finger. *J Transl Intern Med.* 2014;2:132-5.
6. Anderson B, Kaye S. Treatment of flexor tenosynovitis of the hand (Trigger Finger) with corticosteroids: A prospective study of the response to local injection. *Arch*

- Intern Med. 1991;151:153–156.
7. Lorthioir J. Jr. Surgical treatment of trigger-finger by a subcutaneous method. *J Bone Joint Surg Am.* 1958;40:793–795.
 8. Turowski GA, Zdankiewicz PD, Thomson JG. The results of surgical treatment of trigger finger. *J Hand Surg Am.* 1997;22:145–149.
 9. Moore JS. Flexor tendon entrapment of the digits (Trigger finger and trigger thumb) *J Occup Environ Med.* 2000;42:526-45.
 10. Bunnell S. Injuries of the hand. In: *Surgery of the hand.* Philadelphia: JB Lippincott; c1944.
 11. Lunsford D, Valdes K, Hengy S. Conservative management of trigger finger: A systematic review. *J Hand Ther.* 2017;17:302697.
 12. Mol MF, Neuhaus V, Becker SJ, *et al.* Resolution and recurrence rates of idiopathic trigger finger after corticosteroid injection. *Hand (NY).* 2013;8:183-190.
 13. Takahashi M, Sato R, Kondo K, *et al.* Morphological alterations of the tendon and pulley on ultrasound after intrasynovial injection of betamethasone for trigger digit. *Ultrasonography.* 2018;37:134.
 14. Castellanos J, Muñoz-Mahamud E, Domínguez E, *et al.* Long-term effectiveness of corticosteroid injections for trigger finger and thumb. *J Hand Surg. Am.* 2015;40:121-126.
 15. Ryzewicz M, Wolf JM. Trigger digits: Principles, management, and complications. *J Hand Surg [Am].* 2006;31:135-146.
 16. Kerrigan CL, Stanwix MG. Using evidence to minimize the cost of trigger finger care. *J Hand Surg.* 2009;34A:997-1005.
 17. Salim N, Abdullah S, Sapuan J, *et al.* Outcome of corticosteroid injection versus physiotherapy in the treatment of mild trigger fingers. *J Hand Surg Eur.* 2012;37:27-34.
 18. Rhoades CE, Gelberman RH, Manjarris JF. Stenosing tenosynovitis of the fingers and thumb: Results of a prospective trial of steroid injection and splinting. *Clin Orthop.* 1984;190:236-238
 19. Newport ML, Lane LB, Stuchin SA. Treatment of trigger finger by steroid injection. *J Hand Surg.* 1990;15A:748-750
 20. Wang J, Zhao JG, Liang CC. Percutaneous release, open surgery, or corticosteroid injection, which is the best treatment method for trigger digits? *Clin Orthop Relat Res.* 2013;471(6):1879-86. DOI: 10.1007/s11999-012-2716-6. Epub 2012 Dec 4. PMID: 23208122; PMCID: PMC3706641.

How to Cite This Article

Sekar N, Kumar RS, Rakesh M, Krishnan A, Subash Y. Comparing the corticosteroid injection and A1 pulley percutaneous release in treatment of trigger finger: A clinical trial. *International Journal of Orthopaedics Sciences.* 2023;9(3):268-272.

Creative Commons (CC) License

This is an open-access journal, and articles are distributed under the terms of the Creative Commons Attribution-Non Commercial-Share Alike 4.0 International (CC BY-NC-SA 4.0) License, which allows others to remix, tweak, and build upon the work non-commercially, as long as appropriate credit is given and the new creations are licensed under the identical terms.