



# International Journal of Orthopaedics Sciences

E-ISSN: 2395-1958  
P-ISSN: 2706-6630  
IJOS 2023; 9(3): 205-208  
© 2023 IJOS  
<https://www.orthopaper.com>  
Received: 24-04-2023  
Accepted: 21-06-2023

**Dr. Jawahar Mehmood Khan**  
Senior Resident, Department of  
Orthopaedics, Govt. Medical  
College, Srinagar, Jammu and  
Kashmir, India

**Dr. Omeshwar Singh**  
Assistant Professor, Department  
of Orthopaedics, MMMCH,  
Solan, Himachal Pradesh, India

**Dr. Jabreel Muzaffar**  
Senior Resident, Department of  
Orthopaedics, Govt. Medical  
College, Baramulla, Jammu and  
Kashmir, India

**Corresponding Author:**  
**Dr. Jabreel Muzaffar**  
Senior Resident, Department of  
Orthopaedics, Govt. Medical  
College, Baramulla, Jammu and  
Kashmir, India

## Outcome of transforaminal nerve root block injection for lumbar radiculopathy

**Dr. Jawahar Mehmood Khan, Dr. Omeshwar Singh and Dr. Jabreel Muzaffar**

DOI: <https://doi.org/10.22271/ortho.2023.v9.i3c.3429>

### Abstract

**Introduction:** Lumbar radiculopathy is defined as a clinical syndrome of back and leg pain accompanied by sensory, reflex, or motor deficits in a nerve root distribution. Epidural injection of steroids has a significant therapeutic role in mitigating the inflammatory component of Lumbar radiculopathy. Transforaminal approach under image guidance enables targeted drug delivery.

**Aim and Objective:** The aim of this study was to assess the results of selective nerve root blocks with corticosteroids in the management of lumbar radiculopathy.

**Materials and Methods:** A total of 120 patients clinically and radiological (MRI) diagnosed with lumbar disc herniation with backache and radiculopathy, who failed to respond to conservative therapy for a duration of 6 weeks were given c- arm guided root block for the respective nerve root and the results were evaluated using the visual analogue scale (VAS), Oswestry Disability Scale (ODI).

**Results:** The initial VAS was  $8.01 \pm 0.9$  which was reduced to  $3.97 \pm 0.4$  at the final follow-up of 6 months. The initial average SLR was  $43.42 \pm 10.99$  which was increased to an average of  $67.78 \pm 6.23\%$  at the final follow-up. The initial Oswestry Disability Scale (ODI) score was  $82.10 \pm 3.8$  which was reduced to  $40.90 \pm 6.5$  at the final follow-up.

**Conclusion:** Selective nerve root block is an easy and safe method with better short-term, mid-term, and long-term pain relief and improvement in functional disability in cases of lumbar intervertebral disc herniation.

**Keywords:** Sciatica, radiculopathy, intervertebral disc displacement, injections, epidural, steroids

### Introduction

Chronic lumbar radiculopathy is defined as a clinical syndrome of back and leg pain accompanied by sensory, reflex, or motor deficits in a nerve root distribution lasting for more than 12 weeks<sup>[1-4]</sup>. Lumbar radiculopathy (sciatica) with a prevalence of 9.9% to 25% is less prevalent than low back pain alone and is characterized by back pain radiating down the knees to the foot and toes, with variable neurological findings<sup>[5]</sup>. The lifetime prevalence of lumbar radiculopathy has been reported to be 5.3% in men and 3.7% in women<sup>[6, 7]</sup>. Lumbar radiculopathy due to a prolapsed disc resolves spontaneously in 23-48% of patients, but up to 30% will still have pronounced symptoms after one year, 20% will be out of work, and 5-15% will undergo surgery<sup>[8-11]</sup>.

Considering that multiple pathophysiological mechanisms underlie lumbar radiculopathy, diverse modalities of treatment have been developed over the years<sup>[12]</sup>. Steroids have been demonstrated to have a therapeutic role, owing to their anti-inflammatory and nociceptive signal-stabilizing properties<sup>[13-15]</sup>. Three principal techniques are available to deliver medication into the epidural space: caudal, transforaminal and inter-laminar routes. The transforaminal approach is advantageous because corticosteroid preparations can be closely injected into the probable source of the irritated nerve root, and this approach results in better ventral epidural spreading than the inter-laminar approach<sup>[16, 17]</sup>.

This prospective study was designed to assess the efficacy of selective nerve root block with corticosteroids in the management of pain associated with prolapsed lumbar intervertebral disc that didn't get relief from non-surgical pharmacological treatment.

## Materials and Methods

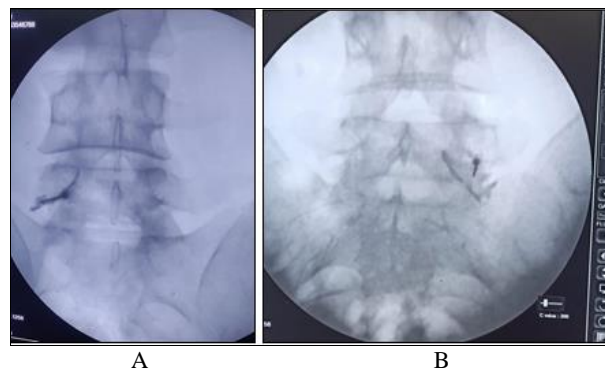
This prospective observational study was carried out at Govt. Bone and Joints Hospital, an associated hospital of Govt. Medical College Srinagar from January 2021 to December 2021. A total of 127 patients with clinically and radiological (MRI) diagnoses of lumbar disc herniation with backache and radiculopathy, who failed to respond to conservative therapy for a duration of 6 weeks and denied the proposed surgical intervention, were included in the study. All patients had a positive straight leg-raising test and some patients had sensory neuro deficit. The exclusion criteria included patients with prior back surgery, impending cauda equine syndrome or with cauda equine syndrome, back or leg pain due to other etiologies (e.g. spinal fracture, metastasis, neuropathy, vascular claudication or neurogenic claudication), pregnancy, breastfeeding status or medical disorders like bleeding diathesis, uncontrolled diabetes, connective tissue disorders, excessive smoking and severe COPD.

The enrolled patients were planned for treatment with selective nerve root block (through transforaminal approach) injections. Detailed information about the type of the procedure and the possible side effects and complications was given to each patient and written informed consent was obtained from all patients before inclusion in the study.

## Intervention

To perform the procedure, the individuals were positioned in ventral decubitus and the injection location was marked with the aid of a fluoroscope. After proper disinfection, the skin and subcutaneous tissue were infiltrated with 2 ml of 2% lidocaine. A 22G (0.70mm) X 3.1/2" rachianesthesia needle was introduced up to the intervertebral foramen, identified with the assistance of the radioscope, and then a non-ionic contrast agent was injected under continuous radioscope visualization to monitor the distribution of the contrast agent in the epidural space and to avoid intravascular injection. Once the correct placement of the needle was confirmed, an infiltration of 2 ml of Methylprednisolone and 3 ml of 2% xylocaine was applied. After the procedure aseptic dressing was done and the patient was monitored for the next 2 hours and then sent home on the same day.

All the patients were instructed to continue conservative treatment with active physical therapy and exercises at home, in addition to using simple analgesics, as needed. They were reevaluated after two weeks, three months, and six months, using the visual analogue scale (VAS) pain score for assessment of current back and lower extremity pain was used and was compared with initial values. Any decrement in the VAS pain scores of more than two scales was considered to be significant. An Oswestry Disability Scale (ODI) was employed to quantitate the level of function (on a 0 to 50-point scale, in which a higher score represented greater disability) and significant improvement and function was described as at least a 40% reduction in ODI.



**Fig 1:** A (C-arm picture showing L5 nerve root on the right side after injecting the dye) and B (C-arm picture showing L5 nerve root on the left side after injecting the dye)

## Results

The mean age of the study population was 38.6 (range 22-65) years. Among 127 included patients there were 79 (65.83%) males and 41 (34.17%) females. In this study, the average duration of pain was 11.40 (range 4-24) months. The most common level of prolapsed disc was L4-L5 in 56 (46.67%) patients followed by L5-S1 in 39 (32.50%) patients, L3-L4 in 18 (15%), L2-L3 in 5 (4.17%) patients and L1-L2 in 2 (1.67%) patients (Table 1). 7 patients were lost to follow-up and they were not included in our statistical data.

**Table 1:** Demographic characters of enrolled patients (N=120, Mean age=38.6 years)

Parameters		No. of patients	Percentage
Gender	Male	79	65.83
	Female	41	34.17
Age group	<40 Years	61	50.83
	40-60 Years	45	37.50
	>60 Years	14	11.67
Duration of pain	<6 Weeks	16	13.33
	6-12 Weeks	21	17.50
	12-18 Weeks	43	35.83
	18-24 Weeks	37	30.83
	>24 Weeks	3	2.50
Herniated discs by level	L1-L2	2	1.67
	L2-L3	5	4.17
	L3-L4	18	15.0
	L4-L5	39	32.50
	L5-S1	56	46.67

All the parameters taken to assess the therapeutic effects showed statistically significant change from initial values to final values. 6 (5%) patients with (L4-5&L5-S1) failed to show a positive response within 3 weeks after the injection.

The initial VAS was  $8.01 \pm 0.9$  which was reduced to  $3.97 \pm 0.4$  at the final follow-up of 6 months. The initial average SLR was  $43.42 \pm 10.99$  which was increased to an average of  $67.78 \pm 6.23\%$  at the final follow-up. The initial Oswestry Disability Scale (ODI) score was  $82.10 \pm 3.8$  which was reduced to  $40.90 \pm 6.5$  at the final follow-up (Table 2). There were no complications observed in our study.

**Table 2:** Showing mean VAS score and ODI at different time periods

Scores	Time periods			
	Initial	6-weeks	3-months	6-months
Visual analogue scale (VAS) Mean $\pm$ SD	$8.01 \pm 0.90$	$2.80 \pm 0.40$	$3.50 \pm 0.70$	$3.97 \pm 0.40$
Oswestry Disability Scale (ODI) Mean $\pm$ SD	$82.10 \pm 3.80$	$35.70 \pm 7.10$	$38.60 \pm 6.10$	$40.90 \pm 6.50$

## Discussion

Since Mixter and Barr first described the correlation between sciatica and disc herniation<sup>[18]</sup> in 1934, both the conservative and surgical modes of treatment for this pathology have evolved significantly. This study reports results from the use of transforaminal block as a component of conservative treatment of sciatic pain secondary to lumbar disc herniation (LDH). The objective of ATB (anaesthetic transforaminal block) in these patients was to reduce the rate of surgery by allowing the patients to tolerate the symptoms for a longer period of time<sup>[19]</sup>. Most patients with symptomatic LDH do not undergo surgical treatment because the course and prognosis are generally favourable, with similar long-term outcomes regardless of the treatment received<sup>[20]</sup>. The natural history of sciatica is of short duration, followed by a phase with residual symptoms. Most patients' symptoms improve within a few weeks with the most severely extruded discs experiencing the greatest rate of size reduction<sup>[21]</sup>. Clinical improvement tends to occur earlier than morphological changes to the disc<sup>[22]</sup>.

Epidural steroid injections for lumbar radiculopathy have been used since 1953. Along with mechanical compression of nerve roots, lumbar radiculopathy can be triggered by different pro-inflammatory chemical agents causing ectopic neuron firing<sup>[23, 24]</sup>. Steroids injected into the epidural space or around the affected nerve root are thought to inhibit these inflammatory mediators. The patients included in this study were selected from among those with persistent symptoms despite conservative treatment and who already presented the criteria for a surgical indication. After the introduction of ATB as a routine treatment for symptomatic LDH, the rate of herniated disc surgeries dropped considerably as compared to the prior experience of other authors.

There are three principal routes being used to deliver medication into the lumbar epidural space: (a) the caudal route, (b) the transforaminal route, and (c) the inter-laminar route. The transforaminal approach is most advantageous as medications are delivered close to the probable source of their rotated nerve root, require the least amount of medication, and this approach results in better ventral epidural spreading of drug than the interlaminar approach but requires a skilled interventionist besides the use of fluoroscopy or a CT scan. There are many studies evaluating the role of lumbar epidural steroid injections (LESI) either by trans-foraminal route or by caudal route in the management of low back pain resulting from various causes<sup>[25-27]</sup>. There are only a few studies where trans-foraminal procedures for PIVD have been reviewed<sup>[28]</sup>.

In our study, we observed that the initial mean VAS was  $8.01 \pm 0.90$ , which reduced to  $3.97 \pm 0.40$  at the final follow-up of 6 months. The reduction of  $4.04 \pm 0.50$  in pain scores was statistically significant. Mehta N *et al*<sup>[29]</sup> did a randomized trial consisting of 120 patients treated with either TFESI or were managed conservatively with a history of persistent LBP with radiculopathy secondary to disc herniation or spinal canal stenosis and they observed that the TFESI group showed statistically significant improvement in all parameters. At the end of 1 month, significant improvement was seen in 93% of patients in the ESI group and 23% of patients treated conservatively when all participants were included. In their study baseline VAS score was  $8.20 \pm 1.10$  which reduced to  $1.13 \pm 0.35$  at 1 month in the TEFSI group. In our study, we observed that the initial ODI was  $82.10 \pm 3.80$ , which was reduced to  $40.90 \pm 6.50$  at the final follow-up. There was a significant decrease in ODI in terms of reduction of disability.

Despite the relatively short follow-up period, the final treatment endpoint was defined for all patients in the study, with the exception of those who abandoned the protocol. Another limitation of this study was that the hernias were not classified by volume and location, due to the diversity of MRI patterns presented.

## Conclusion

Selective nerve root block is an easy and safe method with better short-term and mid-term pain relief and improvement in functional disability in cases of lumbar intervertebral disc herniation.

## Conflict of Interest

The authors declare that they have no known competing financial interests or personal relationships that could have appeared to influence the work reported in this paper.

## Financial Support

Not available

## References

1. Price C, Arden N, Cogan L, Rogers P. Cost-effectiveness and safety of epidural steroids in the management of sciatica. *Health Technol Assess.* 2005;9:1-58.
2. Waddell G. *The back pain revolution.* 2nd ed. Churchill Livingstone; c2004.
3. Fairbank JC. Sciatic: an archaic term. *BMJ.* 2007;335:112.
4. Koes BW, van Tulder MW, Peul WC. Diagnosis and treatment of sciatica. *BMJ.* 2007;334:1313-1317.
5. Van Boxem K, Cheng J, Patijn J, Van Kleef M, Lataster A, Mekhail N, *et al.* 11. Lumbosacral radicular pain. *Pain Pract.* 2010;10(4):339-58.
6. Heliövaara M, Impivaara O, Sievers K, Melkas T, Knecht P, Korpi J, *et al.* Lumbar disc syndrome in Finland. *J Epidemiol Community Health.* 1987;41:251-258.
7. Konstantinou K, Dunn KM. Sciatica: a review of epidemiological studies and prevalence estimates. *Spine (Phila Pa 1976).* 2008;33:2464-2472.
8. Karppinen J, Ohinmaa A, Malmivaara A. Cost-effectiveness of periradicular infiltration for sciatica: subgroup analysis of a randomized controlled trial. *Spine (Phila Pa 1976).* 2001;26:2587-2595.
9. Vad VB, Bhat AL, Lutz GE, Cammisa F. Transforaminal epidural steroid injections in lumbosacral radiculopathy: a prospective randomized study. *Spine (Phila Pa 1976).* 2002;27:11-16.
10. Bush K, Cowan N, Katz DE, Gishen P. The natural history of sciatica associated with disc pathology. A prospective study with clinical and independent radiologic follow-up. *Spine (Phila Pa 1976).* 1992;17:1205-1212.
11. Weber H, Holme I, Amlie E. The natural course of acute sciatica with nerve root symptoms in a double-blind placebo-controlled trial evaluating the effect of piroxicam. *Spine (Phila Pa 1976).* 1993;18:1433-1438.
12. MacVicar J, King W, Landers MH, Bogduk N. The effectiveness of lumbar transforaminal injection of steroids: A comprehensive review with systematic analysis of the published data. *Pain Med.* 2013;14(1):14-28.
13. Li JY, Xie W, Strong JA, Guo QL, Zhang JM. Mechanical hypersensitivity, sympathetic sprouting, and

- glial activation are attenuated by local injection of corticosteroid near the lumbar ganglion in a rat model of neuropathic pain. *Reg Anesth Pain Med.* 2011;36(1):56-62.
14. Ramesh G, Meisner OC, Philipp MT. Anti-inflammatory effects of dexamethasone and meloxicam on *Borrelia burgdorferi*-induced inflammation in neuronal cultures of dorsal root ganglia and myelinating cells of the peripheral nervous system. *J Neuroinflammation.* 2015;12:240.
  15. Johansson A, Hao J, Sjolund B. Local corticosteroid application blocks transmission in normal nociceptive C-fibres. *Acta Anaesthesiol Scand.* 1990;34(5):335-8.
  16. Boswell MV, Hansen HC, Trescot AM, Hirsch JA. Epidural steroids in the management of chronic spinal pain and radiculopathy. *Pain Physician* 2003;6:319-334.
  17. Manchikanti L. Transforaminal lumbar epidural steroid injections. *Pain Physician.* 2000;3:374-398.
  18. Mixter WJ, Barr JS. Rupture of the intervertebral disc with involvement of the spinal cord. *N Engl J Med.* 1934;211:210-4.
  19. Vialle LR, Vialle EN, Suárez Henao JE, Giraldo G. Lumbar disc herniation. *Rev Bras Ortop.* 2015;45(1):17-22.
  20. Jacobs WC, Van Tulder M, Arts M, Rubinstein SM, Van Middelkoop M, Ostelo R, *et al.* Surgery versus conservative management of sciatica due to a lumbar herniated disc: a systematic review. *Eur Spine J.* 2011;20(4):513-22.
  21. Bozzao A, Gallucci M, Masciocchi C, Aprile I, Barile A, Passariello R. Lumbar disk herniation: MR imaging assessment of natural history in patients treated without surgery. *Radiology.* 1992;185(1):135-41.
  22. Komori H, Shinomiya K, Nakai O, Yamaura I, Takeda S, Furuya K. The natural history of herniated nucleus pulposus with radiculopathy. *Spine (Phila Pa 1976).* 1996;21(2):225-9.
  23. Savettieri G, Salemi G, Rocca WA, Meneghini F, D'Arpa A, Morgante L, *et al.* Prevalence of lumbosacral radiculopathy in two Sicilian municipalities. Sicilian Neuro-Epidemiologic Study (SNES) Group. *Acta Neurol Scand.* 1996;93:464-469.
  24. Weinstein JN, Tosteson TD, Lurie JD, Tosteson AN, Hanscom B, Skinner JS, *et al.* Surgical vs nonoperative treatment for lumbar disk herniation: The Spine Patient Outcomes Research Trial (SPORT): A randomized trial. *JAMA.* 2006;296:2441-2450.
  25. Weiner BK, Fraser RD. Foraminal injection for lateral lumbar disc herniation. *J Bone Joint Surg Br* 1997;79:804-807.
  26. Karppinen J, Malmivaara A, Kurunlahti M, Kyllönen E, Pienimäki T, Nieminen P, *et al.* Periradicular infiltration for sciatica: a randomized controlled trial. *Spine* 2001;26:1059-1067.
  27. Pfirrmann CW, Oberholzer PA, Zanetti M, Boos N, Trudell DJ, Resnick D, *et al.* Selective nerve root blocks for the treatment of sciatica: evaluation of injection site and effectiveness- a study with patients and cadavers. *Radiol.* 2001;221:704-711.
  28. Singh S, Kumar S, Chahal G, Verma R. Selective nerve root blocks vs. caudal epidural injection for single level prolapsed lumbar intervertebral disc – A prospective randomized study. *J Clin Orthop Trauma.* 2017;8(2):142-147.
  29. Mehta N, Salaria M, Salaria AQ. Comparison of Fluoroscopic Guided Transforaminal Epidural Injections

of Steroid and Local Anaesthetic with Conservative Management in Patients with Chronic Lumbar Radiculopathies. *Anesth Essays Res.* 2017;11(1):17-22.

#### How to Cite This Article

Khan JM, Singh O, Muzaffar J. Outcome of transforaminal nerve root block injection for lumbar radiculopathy. *International Journal of Orthopaedics Sciences.* 2023;9(3):205-208.

#### Creative Commons (CC) License

This is an open access journal, and articles are distributed under the terms of the Creative Commons Attribution-Non Commercial-Share Alike 4.0 International (CC BY-NC-SA 4.0) License, which allows others to remix, tweak, and build upon the work non-commercially, as long as appropriate credit is given and the new creations are licensed under the identical terms.