



E-ISSN: 2395-1958
P-ISSN: 2706-6630
IJOS 2021; 7(4): 243-248
© 2021 IJOS
www.orthopaper.com
Received: 19-07-2021
Accepted: 29-08-2021

Dr. Siddhant Shah
Assistant Professor, AMC MET
Medical College, Ahmedabad,
Gujarat, India

Dr. Aishwarya Desai
Third Year Resident, AMC MET
Medical College, Ahmedabad,
Gujarat, India

Dr. Bhavik Dalal
Professor and HOD, AMC MET
Medical College, Ahmedabad,
Gujarat, India

Dr. Sneh Shah
Senior Resident, AMC MET
Medical College, Ahmedabad,
Gujarat, India

Dr. Sanket Trivedi
Third Year Resident, AMC MET
Medical College, Ahmedabad,
Gujarat, India

Dr. Homy Modi
Third Year Resident, AMC MET
Medical College, Ahmedabad,
Gujarat, India

Corresponding Author:
Dr. Sneh Shah
Senior Resident, AMC MET
Medical College, Ahmedabad,
Gujarat, India

Study of functional and radiological outcome in humerus shaft fractures treated with anterior bridge plating

Dr. Siddhant Shah, Dr. Aishwarya Desai, Dr. Bhavik Dalal, Dr. Sneh Shah, Dr. Sanket Trivedi and Dr. Homy Modi

DOI: <https://doi.org/10.22271/ortho.2021.v7.i4d.2890>

Abstract

Introduction: In our study we have evaluated functional and radiological outcome in 20 patients. Humerus shaft fractures treated with anterior bridge plating has shown good results in terms of postoperative pain and union time. Though open reduction and internal fixation is gold standard this technique gives good results.

Materials and methods: Twenty patients were treated with anterior bridge plating between July 2020 to may 2021. All cases were treated with 4.5mm DCP in bridging mode. Mechanism of injury, age, gender, union time were taken into account. UCLA shoulder and MEPS score were taken for assessing function.

Results: In this study 20 patients were included, 16 males and 4 females. The age of patients ranged from 20 to 60 years with mean age of 34 years. All the fractures healed within range of 16-18 weeks. No radial nerve palsies were recorded. According to UCLA shoulder score 16 patients were excellent and 4 patients were good. The mayo elbow performance score was above 90 for all patients.

Conclusion: Anterior bridge plating using MIPO technique results in good functional and radiological outcomes. It is safe and less time consuming for simple humerus shaft fracture patterns.

Keywords: Anterior bridge plate, Humerus shaft fractures

Introduction

Humerus shaft fractures are common accounting for 3-5% of all fractures [1]. Various methods have evolved from closed [2-4], external fixation [5], antegrade [6-10] and retrograde [11-15] nailing and plating [16-20] to minimal invasive osteosynthesis [21-22]. Although shaft humerus fractures heal well by nonoperative treatment operative intervention offer a rapid return to function.

Although intramedullary nailing reduces soft tissues injury but leads to shoulder dysfunction or pain as a result [23-24].

Minimal invasive technique was developed to achieve biologic fixation, reducing complications of open reduction. The incision used is small and away from fracture site to avoid exposure reducing risk of infection, nonunion [25].

The aim of this study was to evaluate functional and radiological outcome of humerus shaft fractures treated with anterior bridge plating.

Materials and methods

Twenty patients were treated by minimal invasive technique from July 2020 to May 2021.

The inclusion criteria were

- 1) Patients between 20 to 60 years
- 2) Closed fractures
- 3) Patients with displaced fractures who could not tolerate prolonged immobilization
- 4) Displaced fractures with >3cm shortening and >20° angulation.

The exclusion criteria included

- 1) Nondisplaced fractures

- 2) fractures of distal third humerus with intraarticular extension
- 3) pathological fractures
- 4) open fractures
- 5) neurovascular injuries.

The study included twenty patients (9 males and 3 females). The mechanism of injury was fall from height on outstretched hand and road traffic accident. All fractures were unilateral. The classification used was AO.13 patients were type A,6 were type B and 1 type C. All patients presented to emergency department immediately following injury with pain, swelling and deformity. A U slab was given to reduce pain and gravity assisted reduction of fracture.

Shoulder function was assessed using UCLA system, the parameters include pain (10 points), motion (10 points), function (10 points) and patient satisfaction (10 points).the scores are divided into excellent (34 to 35 points), good (29 to 33 points), fair(21 to 28 points) and poor (0 to 20 points).

Elbow function was assessed by using mayo elbow performance score which uses 100 point scale regarding pain (45 points), range of motion (20 points), stability (10 points) and function (25 points). Scores divided as excellent (>90points), good(75 to 89points), fair(60 to 74 points) or poor (<59 points).

Surgical technique: The patient placed in supine position on radiolucent table with arm in 90⁰ degree abduction and supination. First 4.5 narrow LCDCP was taken for appropriate length and incisions were marked. First incision was made

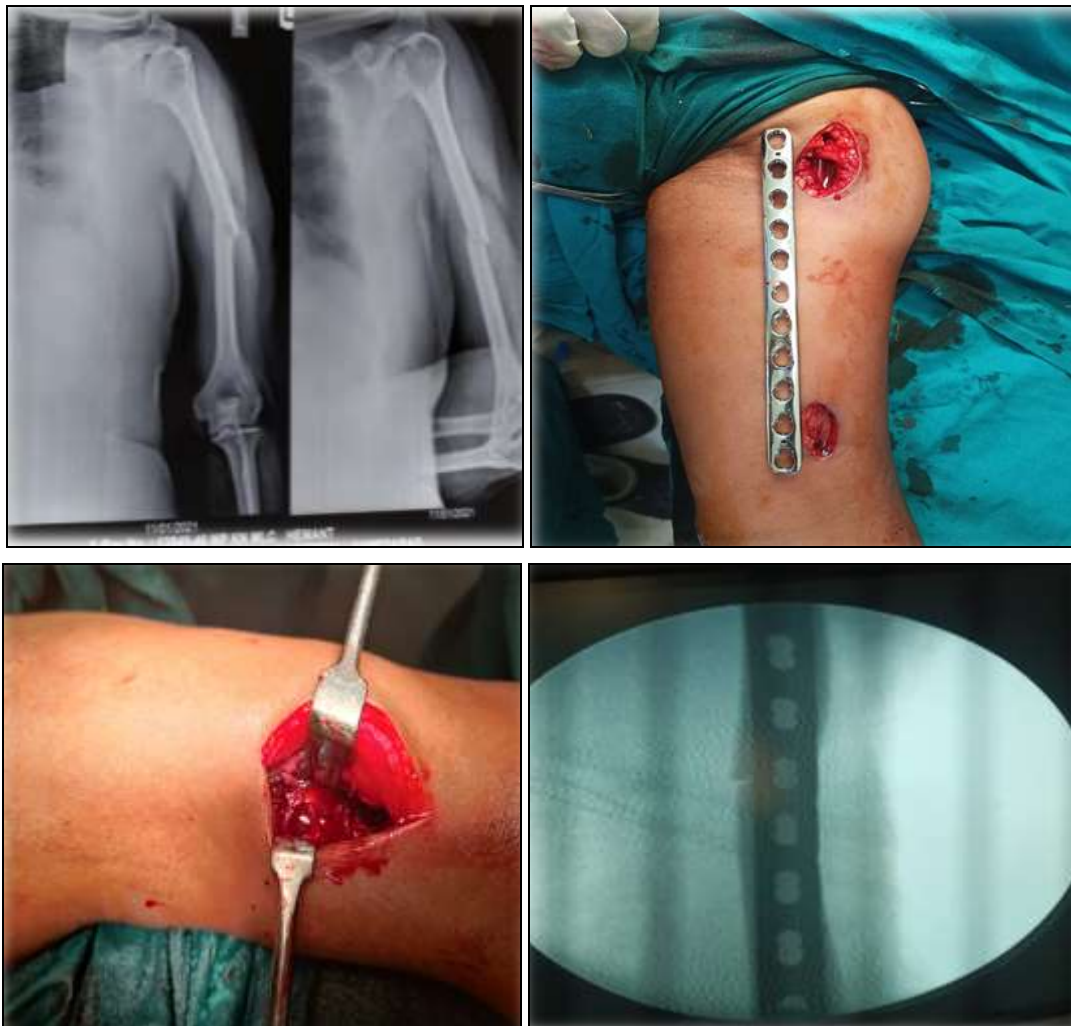after confirming on C arm about 2cm length between deltoid laterally and brachialis medially. The anterior border of humerus shaft runs from greater tubercle proximally to coronoid fossa distally.

Distally 2 cm incision was made about 1cm proximal to elbow crease. Dissection done between biceps and brachialis and anterior cortex was exposed. A submuscular periosteal tunnel was prepared by Cobb elevator from proximal and distal incisions. Anarrow 4.5 LCDCP was inserted from proximal incision with help of sleeve. One assistant maintains supination with traction to prevent shortening. Provisional fixation was done with 2 k wires in proximal and distal incision.

When appropriate length of humerus was restored and both ends of plate were in correct position the proximal and distal ends of plate were fixed to bone respectively. 2 screws were inserted in proximal and distal ends and not tightened.

The k wires were removed and alignment and apposition was checked of fragments and if any malalignment was corrected. When alignment was achieved screws were tightened and remaining fixation was completed by inserting total 3 screws in each fragment. Final positioning checked in C arm in both anteroposterior and lateral views.

Postoperative protocol: Postoperatively all patients were given functional humerus brace and mobilization started postoperative day 1.All patients were followed at 15 days postoperatively for suture removal followed by followup at 1 month, 3 months, 6 months and 1 year respectively.



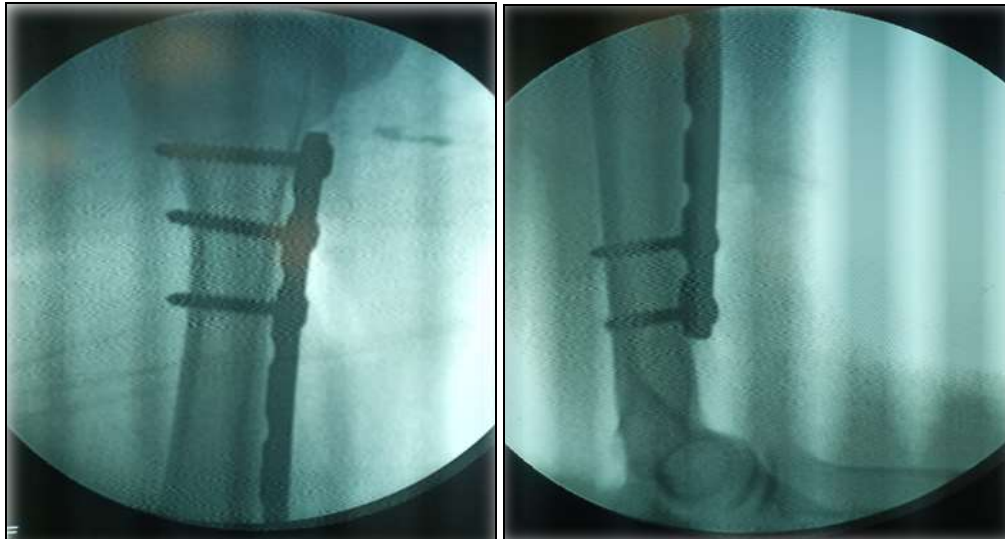

Fig 1-6: Preoperative x-ray, incision, plate length, IITV fracture reduction

Results

In this study 20 patients were included, 16 males and 4 females. The age of patients ranged from 20 to 60 years with mean age of 34 years. 60% injuries were due to RTA, 25% injuries due to domestic fall and remaining 15% due to assault. Of 20 patients, 85% fracture pattern was 12A2, 10% were 12A1 and 1 pattern included 12C3 pattern. All the patients were followed up with range of 8 months to 12 months.

All the fractures healed within range of 16-18 weeks. No radial nerve palsies were recorded. The average active forward flexion was about 175° (140-170°), external rotation was 65° (48-80°) and internal rotation of 69° (55-80°). According to UCLA shoulder score 16 patients were excellent and 4 patients were good. The mayo elbow performance score was above 90 for all patients. The operating time ranged from 40 minutes to 70 minutes.

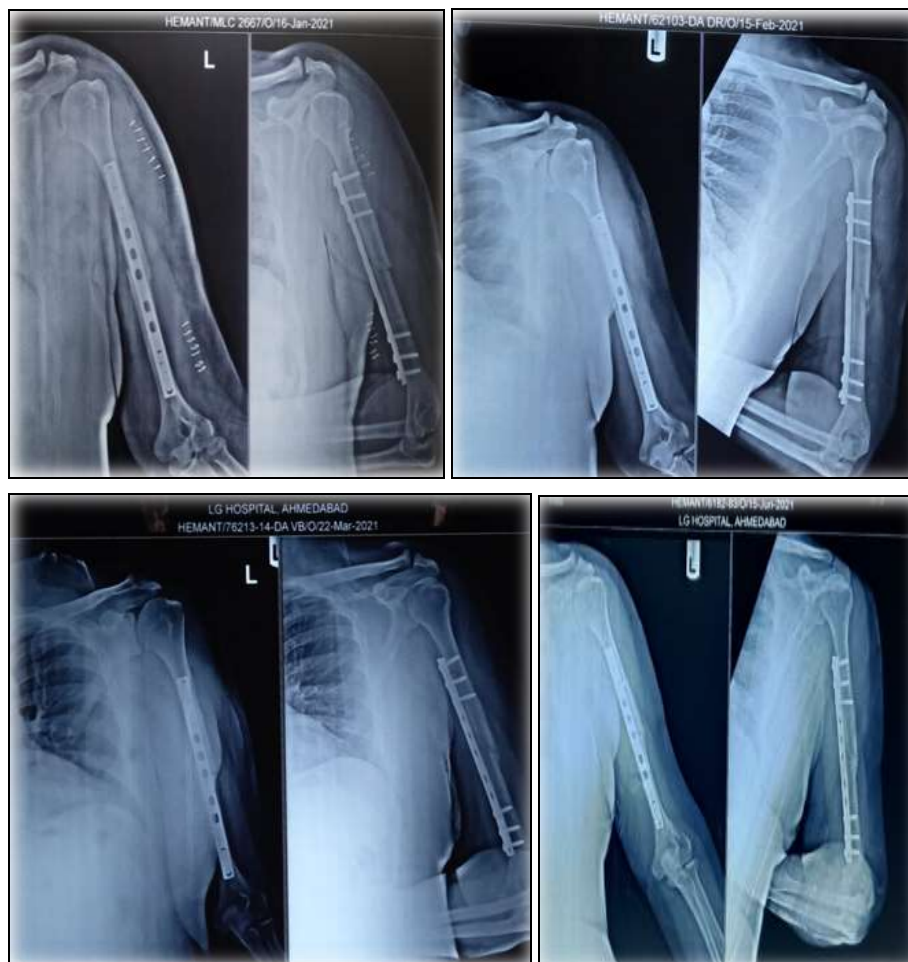


Fig 7-10: Postoperative x-ray, 1 month, 3 months, 6 months follow-up x-rays.

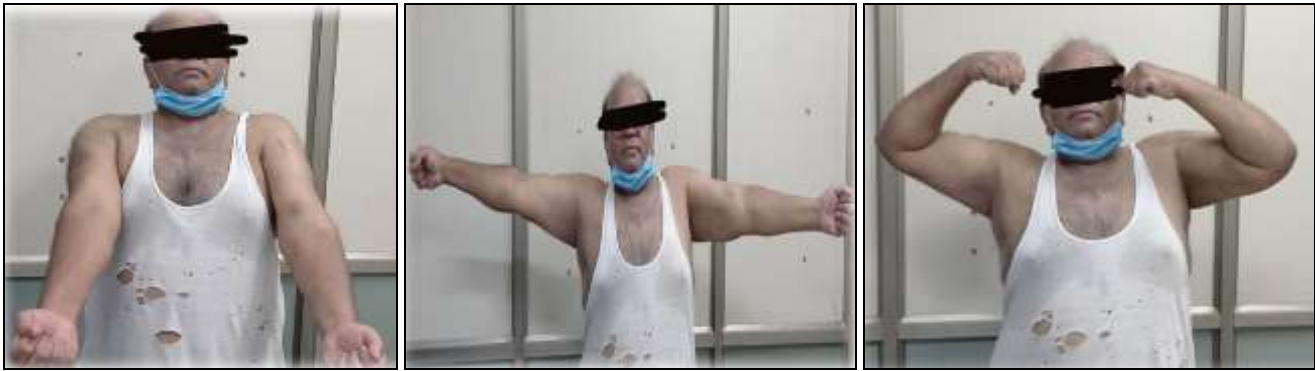

Fig 11-13: forward flexion, extension and flexion

Table 1: The patient data and results of patients treated with anterior bridge plating

No	agesex	mechanism of injury	time to union(weeks)	abduction/forward flexion(degrees)	flexion/extension(degrees)	UCLA score	MEPS
1	25 M	RTA	16	90/160	130/0	34	100
2	28 M	RTA	12	90/170	130/0	34	100
3	35 M	RTA	15	90/165	135/0	35	100
4	30 M	DOMESTIC FALL	16	90/170	140/5	34	100
5	32 M	ASSAULT	20	90/170	140/0	35	100
6	27 M	RTA	16	90/170	135/0	31	100
7	26 F	RTA	12	90/170	140/0	34	100
8	25 M	RTA	22	90/170	130/10	34	95
9	30 F	DOMESTIC FALL	30	90/170	135/0	33	100
10	31 F	RTA	26	90/170	140/5	35	90
11	28 M	RTA	12	90/150	140/0	35	95
12	45 M	DOMESTIC FALL	16	90/160	135/0	34	95
13	56 M	DOMESTIC FALL	16	90/170	140/0	34	95
14	34 M	ASSAULT	18	90/150	130/5	35	95
15	55 M	RTA	12	90/160	135/0	34	100
16	50 F	RTA	12	90/150	140/0	35	100
17	47 M	DOMESTIC FALL	16	90/130	135/0	30	100
18	22 M	RTA	19	90/170	130/0	28	100
19	26 M	ASSAULT	20	90/170	130/0	34	95
20	30 M	RTA	21	90/160	130/0	34	95

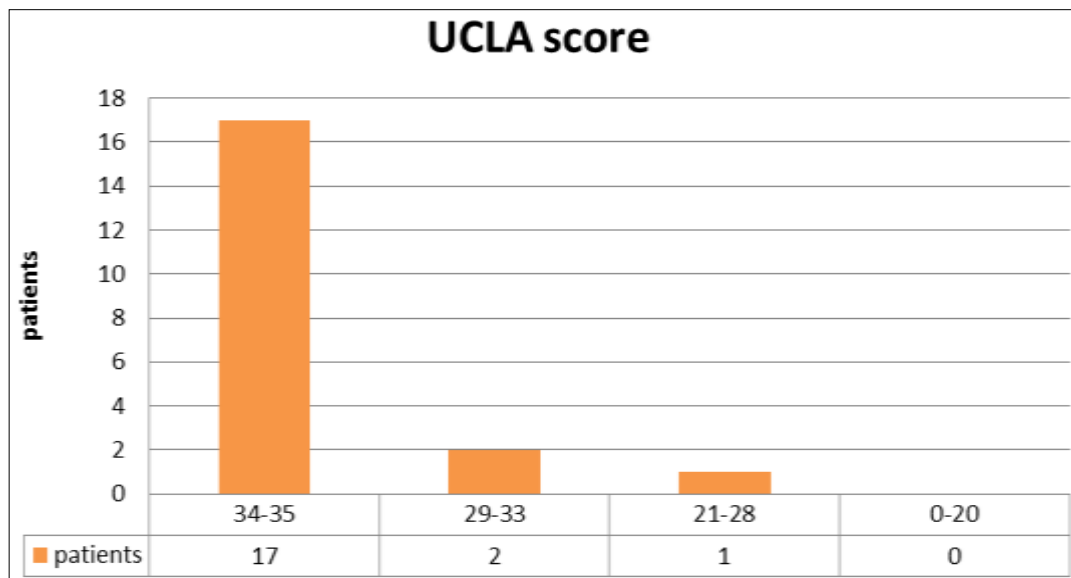


Fig 14: Functional outcome using UCLA score

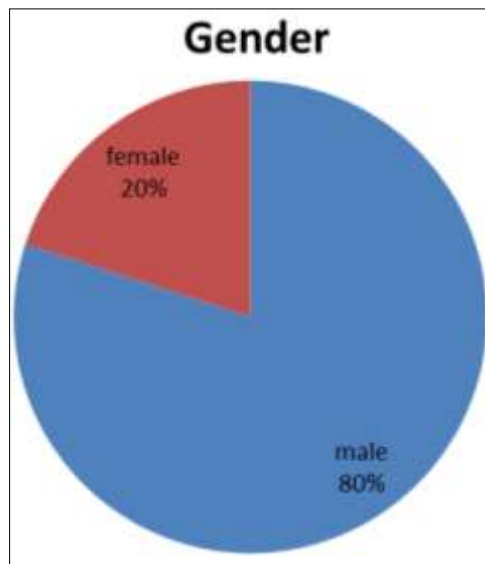


Fig 15: Gender distribution

Discussion

In this study acute displaced humerus shaft were treated with minimal invasive technique and satisfactory clinical and radiological outcome was obtained. Open reduction and internal fixation is considered treatment of choice for humerus shaft fractures. Complications include infection, refracture, iatrogenic nerve palsy [26-28]. Nonunion rate of open plating reported to be as high as 5.8% and iatrogenic nerve palsy from 5.1% to 17.6% [27, 28]. Open reduction is associated with soft tissue stripping and disruption of periosteal blood supply. When MIPO using an anterior placed plate is applied to treat humerus shaft, neither fracture nor radial nerves need to be dissected [29, 30]. In our study there were no radial nerve palsies.

MIPO has several advantages of small skin incision, short immobilization period, reducing chances of nonunion due to open reduction. Complications can be reduced with thorough anatomical knowledge and skillful surgical technique.

Conclusion

From this study we conclude that minimal invasive technique is a safe and effective way to treat humerus shaft fractures as it provides good clinical and radiological outcome.

It is based on relative stability which provides healing and formation of callus reducing possibility of infection and nonunion.

Although technically demanding, lack of neurological compromise, good outcomes are obtained in terms of union, shoulder and elbow functions.

References

1. Volgas DA, Stannard JP, Alonso JE. Nonunions of the humerus. *Clin Orthop Relat Res* 2004;419:46-50.
2. Koch PP, Gross DF, Gerber C. The results of functional (Sarmiento) bracing of humeral shaft fractures. *J Shoulder Elbow Surg* 2002;11:143-150.
3. Pehlivan O. Functional treatment of the distal third humeral shaft fractures. *Arch Orthop Trauma Surg* 2002;122:390-395.
4. Toivanen JA, Nieminen J, Laine HJ, *et al.* Functional treatment of closed humeral shaft fractures. *Int Orthop*. 2005;29:10-13.
5. Flinkkila T, Hyvonen P, Lakovaara M, *et al.* Intramedullary nailing of humeral shaft fractures. A

- retrospective study of 126 cases. *Acta Orthop Scand* 1999;70:133-136.
6. Lin J, Hou SM. Antegrade locked nailing for humeral shaft fractures. *Clin Orthop Relat Res* 1999;365:201-210
7. Cox MA, Dolan M, Synnott K, *et al.* Closed interlocking nailing of humeral shaft fractures with the Russell-Taylor nail. *J Orthop Trauma* 2000;14:349-353.
8. Ajmal M, O'Sullivan M, McCabe J, *et al.* Antegrade locked intramedullary nailing in humeral shaft fractures. *Injury*. 2001;32:692-694.
9. Petsatodes G, Karataglis D, Papadopoulos P, *et al.* Antegrade interlocking nailing of humeral shaft fractures. *J Orthop Sci* 2004;9:247-252.
10. Rommens PM, Verbruggen J, Broos PL. Retrograde locked nailing of humeral shaft fractures. A review of 39 patients. *J Bone Joint Surg Br.* 1995;77:84-89.
11. Rommens PM, Verbruggen J, Broos PL. Retrograde locked nailing of humeral shaft fractures. A review of 39 patients. *J Bone Joint Surg Br.* 1995;77:84-89.
12. Rommens PM, Blum J, Runkel M. Retrograde nailing of humeral shaft fractures. *Clin Orthop Relat Res.* 1998;350:26-39.
13. Simon P, Jobard D, Bistour L, *et al.* Complications of Marchetti locked nailing for humeral shaft fractures. *Int Orthop* 1999;23:320-324.
14. Sanzana ES, Dummer RE, Castro JP, *et al.* Intramedullary nailing of humeral shaft fractures. *Int Orthop* 2002;26:211-213.
15. Fernandez FF, Matschke S, Hulsenbeck A, *et al.* Five years' clinical experience with the unreamed humeral nail in the treatment of humeral shaft fractures. *Injury*. 2004;35:264-271.
16. Vander GR, Tomasin J, Ward EF. Open reduction and internal fixation of humeral shaft fractures. Results using AO plating techniques. *J Bone Joint Surg Am* 1986;68:430-433.
17. abezies EJ, Banta CJ 2nd, Murphy CP, *et al.* Plate fixation of the humeral shaft for acute fractures, with and without radial nerve injuries. *J Orthop Trauma.* 1992;6:10-13.
18. Meekers FS, Broos PL. Operative treatment of humeral shaft fractures. The Leuven experience. *Acta Orthop Belg* 2002;68:462-470.
19. Niall DM, O'Mahony J, McElwain JP. Plating of humeral shaft fractures—has the pendulum swung back? *Injury*. 2004;35:580-586.
20. Levy JC, Kalandiak SP, Hutson JJ, *et al.* An alternative method of osteosynthesis for distal humeral shaft fractures. *J Orthop Trauma* 2005;19:43-47.
21. Livani B, Belangero WD. Bridging plate osteosynthesis of humeral shaft fractures. *Injury* 2004;35:587-595
22. Yang KH. Helical plate fixation for treatment of comminuted fractures of the proximal and middle one-third of the humerus. *Injury*. 2005;36:75-80.
23. Apivatthakakul T, Arpornchayanon O, Bavornratanavech S. Minimally invasive plate osteosynthesis (MIPO) of the humeral shaft fracture. Is it possible? A cadaveric study and preliminary report. *Injury* 2005;36:530-538.
24. Flinkkila T, Hyvonen P, Lakovaara M, *et al.* Intramedullary nailing of humeral shaft fractures. A retrospective study of 126 cases. *Acta Orthop Scand.* 1999;70:133-136.
25. Rommens PM, Blum J, Runkel M. Retrograde nailing of humeral shaft fractures. *Clin Orthop Relat Res.* 1998;350:26-39.

26. Farouk O, Krettek C, Miclau T, *et al.* Minimally invasive plate osteosynthesis and vascularity: Preliminary results of a cadaver injection study. *Injury* 1997;28(1):7-12.
27. Jawa A, McCarty P, Doornberg J, *et al.* Extra-articular distal-third diaphyseal fractures of the humerus. A comparison of functional bracing and plate fixation. *J Bone Joint Surg Am* 2006;88-a:2343-2347.
28. Lim KE, Yap CK, Ong SC, *et al.* plate osteosynthesis of the humerus shaft fracture and its association with radial nerve injury- a retrospective study in Melaka General Hospital. *Med J Malaysia* 2001;56(c):8-12.
29. Paris H, Tropiano P, Clouet D'orval B, *et al.* Fractures of the shaft of the humerus: systemic plate fixation. Anatomic and functional results in 156 cases and a review of the literature. *Rev Chir Orthop Reparatrice Appar Mot* 2000;86:346-359.
30. Apivatthakakul T, Arpornchayanon O, Bavornratanavech S. Minimally invasive plate osteosynthesis (MIPO) of the humeral shaft fracture. Is it possible? A cadaveric study and preliminary report. *Injury* 2005;36:530-538.
31. Pospula W, Abu Noor T. Percutaneous Fixation of Comminuted Fractures of the Humerus: Initial Experience at Al Razi Hospital, Kuwait. *Med Princ Pract* 2006;15:423-426.