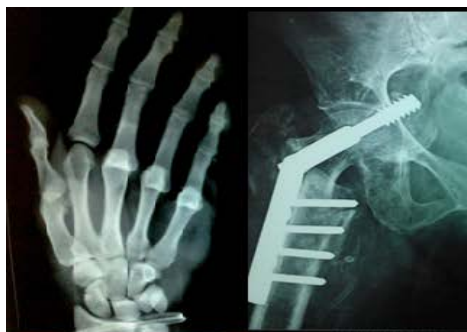



## International Journal of Orthopaedics Sciences

E-ISSN: 2395-1958  
P-ISSN: 2706-6630  
IJOS 2021; 7(4): 09-13  
© 2021 IJOS  
[www.orthopaper.com](http://www.orthopaper.com)  
Received: 05-08-2021  
Accepted: 10-09-2021

**Dr. N Vishnu Vardhan**  
Associate Professor, Department  
of orthopaedics, Narayana  
medical college and hospital  
Chinthareddypalem, Nellore,  
Andhra Pradesh, India

**Dr. T Dhorababu**  
Postgraduate Resident,  
Department of orthopaedics  
Narayana medical college and  
hospital Chinthareddypalem,  
Nellore, Andhra Pradesh, India

### Evaluation of functional outcome after open reduction and internal fixation of distal femur fractures by locking compression plate

**Dr. N Vishnu Vardhan and Dr. T Dhorababu**

**DOI:** <https://doi.org/10.22271/ortho.2021.v7.i4a.2858>

#### Abstract

**Background:** In the supra and intercondylar fractures of femur particularly with intra articular extension, patient may develop stiffness of knee, shortening, rotational deformities, internal derangement of knee with instability, varus and valgus deformities which affect patient's routine lifestyle. If these cases were treated with locking compression plate, the results obtained were successful, superior, timesaving providing early ambulation and least disability improving the functional outcome.

**Materials and Methods:** This is a prospective interventional study. This study includes 25 supracondylar and intercondylar fractures of femur (both Muller's Type 'A', Type B and Type 'C' fractures) treated with open reduction and internal fixation by Locking Compression Plate in the Department of Orthopaedics, Narayana Medical College and Hospital, Nellore from October 2019 to August 2021. There are 16 males and 9 females with age ranging from 20 to 80 years with an average of 44.6 years. Average age for males is 28.9 years and average age for females is 25 years. 18 fractures were due to road traffic accidents and 6 cases are due to fall from significant heights, 1 case due to simple fall from standing (osteoporosis). 15 cases were in right femur (60%) and 10 cases were in left femur (40%).

**Results:** 25 cases were included in the study. There is an increase in the rate of union, decreased time taken for union, increased knee range of motion, decreased time for weight-bearing, postoperative complications and duration for hospital stay.

**Conclusion:** LCP proved to be a good implant which could take the challenges like poor bone stock, severe comminution both metaphyseal and articular and prove successful. The locking head screws distally have prevented varus collapse, even in cases of osteoporosis. The Condylar LCP can be used in either an open or a minimally invasive manner.

**Keywords:** Distal femur fracture, osteosynthesis, internal fixation

#### Introduction

In the supra and intercondylar fractures of femur particularly with intra-articular extension, patient may develop stiffness of knee, shortening, rotational deformities, internal derangement of knee with instability, varus and valgus deformities which affect patient's routine lifestyle. If these cases were treated with locking compression plate, the results obtained were successful, superior, timesaving providing early ambulation and least disability improving the functional outcome. Comparative study of management of distal femoral fractures managed by DCS and distal femoral LCP (25 cases each) and concluded that results were similar except that distal femur LCP is better in comminuted fractures <sup>[1]</sup>.

Study on biomechanical analysis of distal femur fracture fixation using LCP versus condylar blade plate concluded that LCP proved stronger than blade plate in both cyclic loading and ultimate strength in biomechanical testing <sup>[2]</sup>.

The overall results of surgical management of distal femoral fractures with DCS are similar to those obtained with condylar blade plate <sup>[3]</sup>. Compared the outcomes of distal femoral fractures treated by bridge plate osteosynthesis using dynamic condylar screw versus retrograde intramedullary supracondylar nail. The DCS group presented significantly better results than the RIMSN group. Blood loss was significantly more in the DCS group. No significant differences between the two groups were seen in terms of cumulative rate of union, range of

**Corresponding Author:**  
**Dr. N Vishnu Vardhan**  
Associate Professor, Department  
of orthopaedics, Narayana  
medical college and hospital  
Chinthareddypalem, Nellore,  
Andhra Pradesh, India

motion of the knee, overall results, and complications [4].

### Aims and Objectives

To evaluate the results of open reduction and internal fixation of distal femur fractures by LCP. The primary efficacy end point is rate of fracture healing. Secondary end points included reduction of fracture, stability and reduction in complications.

### Materials and Methods

This is a prospective interventional study. This study includes 25 Supracondylar and intercondylar fractures of femur (Both Muller's Type 'A', Type B and Type 'C' fractures) treated with open reduction and internal fixation by Locking Compression Plate in the Department of Orthopaedics, Narayana Medical College and Hospital, Nellore from October 2019 to August 2021.

There are 16 males and 9 females with age ranging from 20 to 80 years with an average of 44.6 years. Average age for males is 28.9 years and average age for females is 25 years. 18 fractures were due to road traffic accidents and 6 cases are due to fall from significant heights, 1 case due to simple fall from standing (osteoporosis). 15 cases were in right femur (60%) and 10 cases were in left femur (40%).

### The Inclusion Criteria

1. Patients who have been diagnosed as Closed Type 1, 2 compound distal femur fractures.
2. Age group of 20–80 years of both sexes.

### The Exclusion Criteria

1. Skeletally immature individuals.
2. Type 3 compound fractures of distal femur.
3. Fractures associated with knee dislocation.
4. Patients with associated ipsilateral tibia and foot fractures.
5. Pathological Fractures.

All the patients were immediately admitted and in detail general examination was done for complete assessment like head injuries, spine, chest, abdomen, pelvis and limbs. In patients with severe blood loss and in hypovolaemic shock, it was corrected with intravenous fluids and blood. For simple fractures, antibiotic regimen was started 12 hours before surgery parenterally and continued till 3rd postoperative day, from then till 10th post-operative day oral antibiotics were given.

For functional evaluation of the results, we have taken the criteria of 2 functional scoring systems which were used by previous workers.

1. Neer's functional scoring system.
2. Sanders functional evaluation scale.

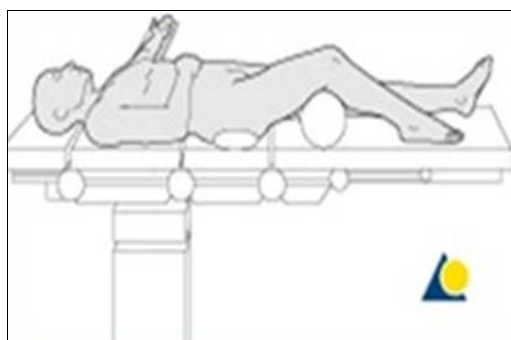


Fig 1: Procedure

### Supine Position, Knee Flexed 30°

The patient was placed supine on a radiolucent table with the knee in 30° flexion. The knee was supported by a cushion or rolled sheets and a small sandbag was placed just behind the same buttock to prevent external rotation of the limb.

**Lateral/Anterolateral Approach:** The lateral approach to the distal femur allows for visualization, reduction, and fixation of simple articular fractures of the distal femur.

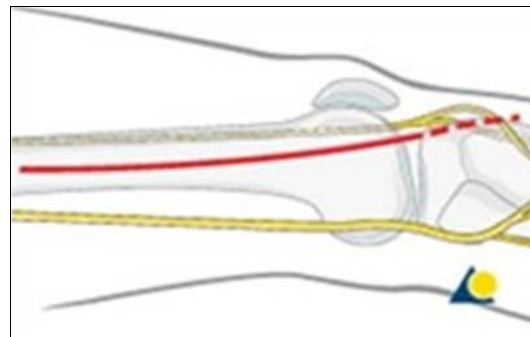


Fig 2: Skin Incision

Begin the skin incision in the mid-lateral line of the femoral shaft and curve it anteriorly over the lateral femoral condyle, towards the tibial tubercle.

**Division of the Iliotibial Band:** Divide the iliotibial band (tract) in line with the skin incision.

**Elevation of Vastus Lateralis:** Incise the muscle fascia investing the vastus lateralis just anterior to the lateral intermuscular septum and elevate the muscle fibres off the septum, working from distal to proximal.

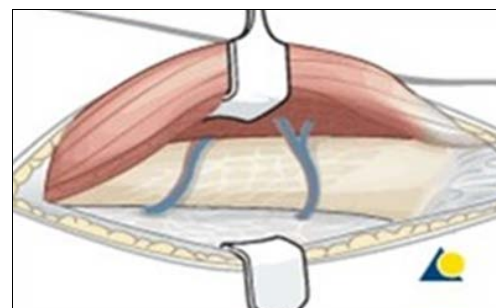


Fig 3: Elevation of Vastus Lateralis

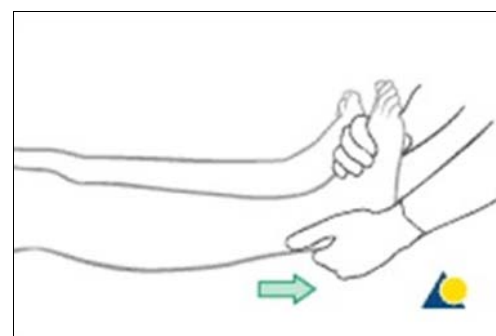
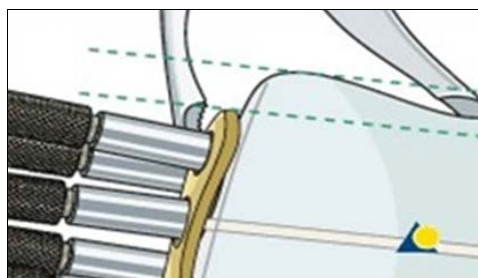


Fig 4: Reduction of the Metaphysis/Diaphysis

The key concept in reduction of the metaphyseal component of the fracture when using a Condylar LCP is that proper application of the Condylar LCP on the distal femur allows the surgeon to use the plate to achieve the metaphyseal

fracture reduction. When brought down to the proximal femoral shaft, the correct frontal plane alignment has been assured.

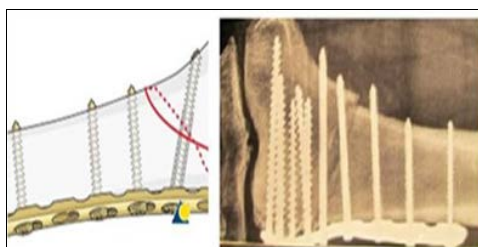
**Assembly of Condylar LCP:** Screw the threaded guide wires for the 2.5 mm guide wire into the 5.0 mm and 7.3 mm screw holes of the plate head.



**Fig 5:** Assembly of Condylar LCP

- The guide wire inserted through the 7.3 mm central hole is parallel to both the tibiofemoral joint plane and the patella-femoral joint
- The guide wires inserted through any of the four most distal 5.0 mm screw holes in the head of the plate are parallel to the tibiofemoral joint plane.

**Distal Screw Insertion:** With the central guide wire parallel to the tibiofemoral joint surface and the plate flush on the lateral femoral cortex, the central screw (7.3 mm) is inserted over the guide wire. Inserting only one screw at this point allows correction of small deformities in the sagittal plane (on the lateral x-ray). After you have confirmed that the plate is in the correct position on the distal femur, when viewed on a lateral x-ray, the additional screws (5.0 mm) should be inserted into the distal femoral articular block.



**Fig 6:** Fixation of Plate to Proximal Fragment

### Insertion of Additional Proximal Screws

#### Observations and results

25 Cases of Distal Femur Fractures treated with Open reduction and internal fixation with Locking Compression Plate in the Department of Orthopaedics, Narayana Medical College and Hospital, Nellore from October 2019 to August 2021.

All cases showed radiological and clinical union between 12 weeks to 24 weeks. An average total 'A' type fractures have taken 17.43 weeks for healing (14 out of 25), Muller's type B fractures took 12.7 wks. (4 out of 25) and Muller's 'C' type fractures have taken 16.24 weeks of average time (7 of 20 cases) and 25 cases have taken average time of 15.7 weeks for healing. Range is 12 weeks to 24 weeks.

According to fracture type and knee ROM: 12 cases of 'A' type fractures achieved average knee ROM 105.70, 4 cases of 'B' achieved 950 and 7 cases of 'C' achieved 950 and total average for this study was 92.60.

Total average hospital stay was 18.5 days with a minimum of 15 days and maximum of 27 days.

According to the fracture type and average time of partial weight-bearing and full weight-bearing: - 6 cases of type 'A' 1 fractures have taken average partial weight-bearing of 6.5 weeks and 12.5 weeks for full weight-bearing. Of the type 'A 2' fractures, average partial weight-bearing was at 6 weeks and full weight-bearing at 13.5 weeks. In 'A 3' fractures, average partial weight-bearing time of 8 weeks and 13.9 weeks for full weight-bearing.

In type B fractures, B1 took 6 wks. for partial weight-bearing, 12 wks. for full weight-bearing and B2 fractures took 6.5 wks. for partial weight-bearing and 12 wks. for full weight-bearing. In type C1 fractures, partial weight-bearing started at 7.5 wks. and full weight-bearing at 15 wks. In type C2 fractures, partial weight-bearing has taken 7 weeks and 15.3 weeks for full weight-bearing. In type C3 fractures, 16 weeks for partial weight-bearing and 17 wks. for full weight-bearing. For 25 cases, average full weight-bearing has taken 13.5 weeks. The average time gap between date of injury and date of surgery was 7.33 days.

### Discussion

Fractures of distal femur were amongst the most difficult fractures to treat effectively. The status of the soft tissues, the amount of comminution sustained at the time of injury affect the treatment modality and long term clinical results. The primary goal of operative management is to anatomically align the fracture fragments while providing enough stability to provide early motion.

The locking compression plate makes accurate reduction and fixation easier particularly when the fractures are intra-articular. This study was done to determine the functional evaluation of outcome of distal femur fractures treated with LCP.

We evaluated our results and compared them with those obtained by various other studies, our analysis is as follows.

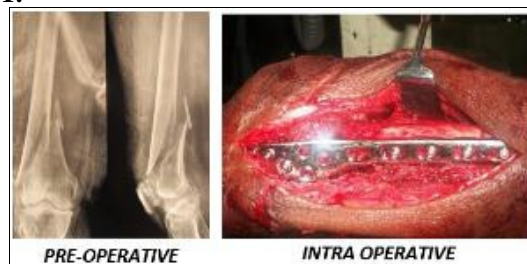The average time for fracture union in various studies was 12-24 weeks. Our study had an average fracture union of 15.7 weeks which was well comparable with studies conducted using Locking Compression Plate.

In our study using Neer's criteria, there were 8 excellent results (32%), 12 good results (48%), 4 fair (16%) and 1 poor (4%) result. Sander's criteria showed 7 excellent (28%), 11 good results (44%), 6 fair (24%) and 1 poor result (4%).

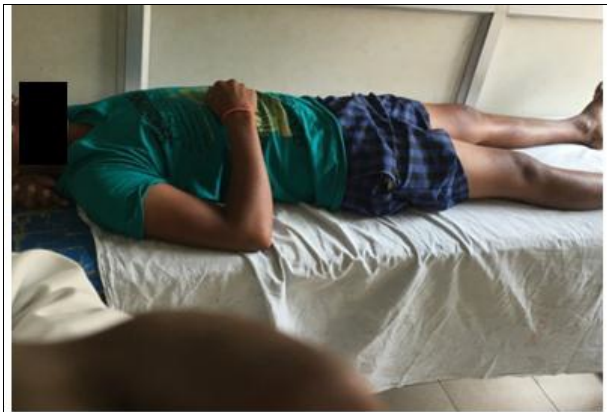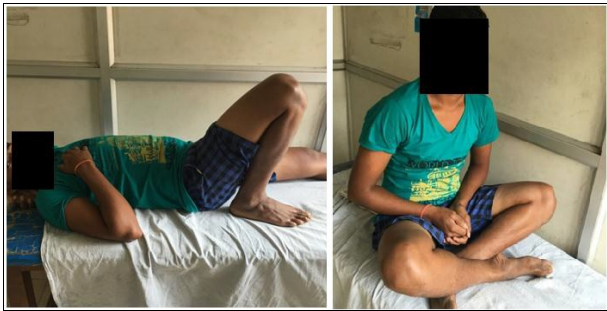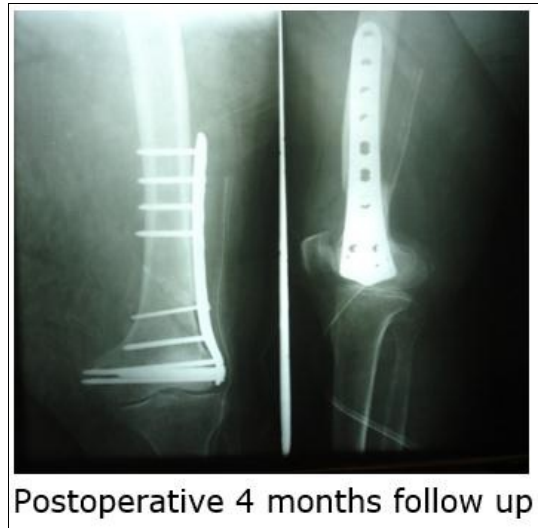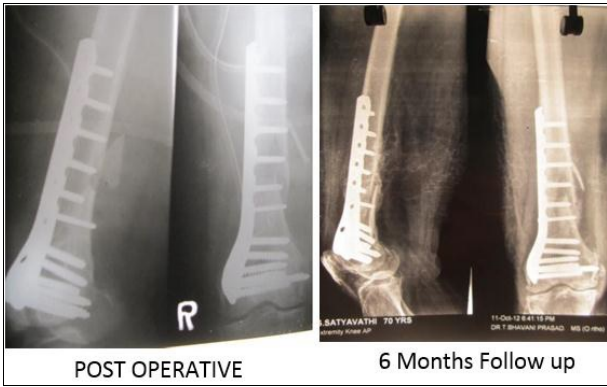
There are no cases with knee instability in this series. We have done primary bone grafting in one case. There was only one case of superficial infection which was controlled with good wound care and oral antibiotics. All incisions healed well. There were no implant failures in the study.

Surgical complications were noted in 12.6% of cases. 11 cases (9.9%) developed hardware failure. 10.7% cases developed non-union. Postoperative staged bone grafting was done in 16% of cases.

### Case 1:

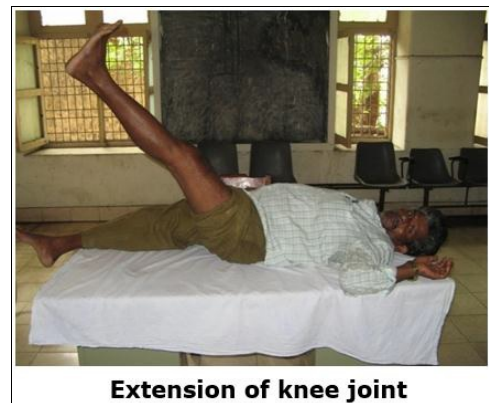
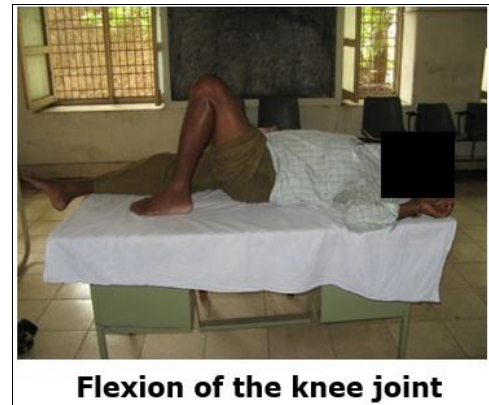
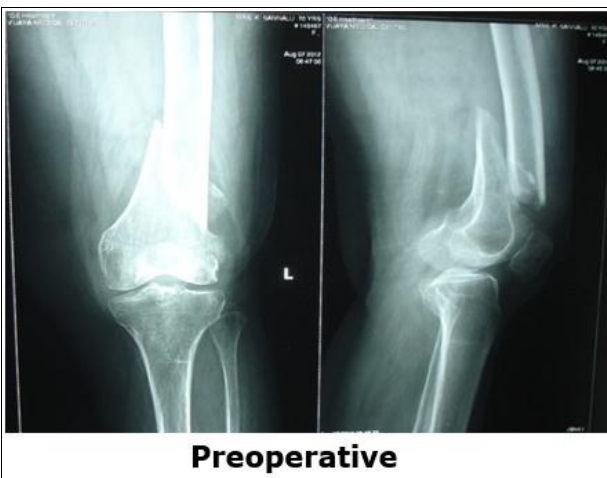

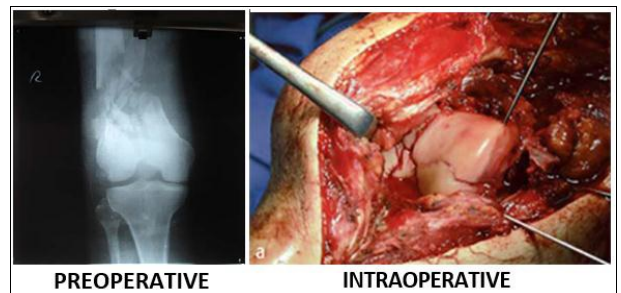


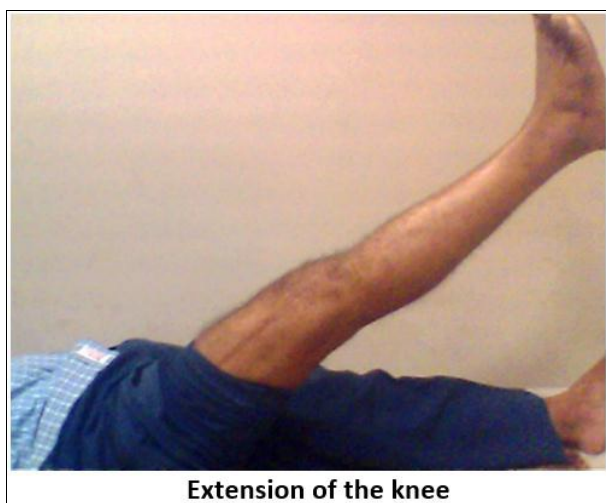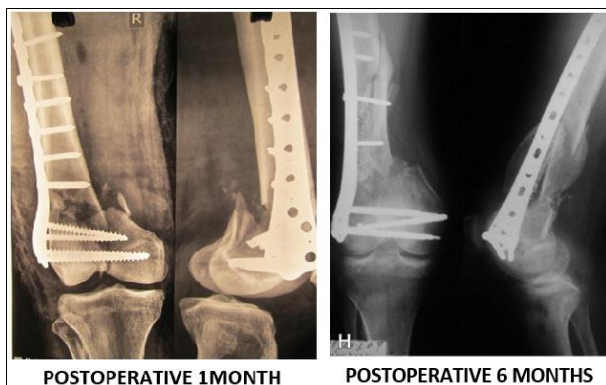
**Fig 7: Flexion of knee joint & Extension of knee joint**

**Case 2:**



**Case 3:**





Extension of the knee

fractures, found higher rates of union in plating but further analysis revealed that clinical outcome may largely depend on surgical technique rather than choice of the implant.<sup>5</sup>

Hahn *et al.*<sup>[6]</sup> reported the outcomes of a Locking Compression Plate in distal femoral fractures. There were low postoperative infection rates, and 75% excellent and satisfactory results were obtained.

Marti *et al.*<sup>[7]</sup> compared the biomechanical properties of less invasive stabilization system (LISS) with those of Condylar buttress plate and LCP. The LISS allowed higher elastic deformation other than systems, placing it between rigid fixation and intramedullary nailing<sup>[7]</sup>.

## References

1. Valles JF, Rodriguez FR. Distal femur fractures Comparative analysis of two different surgical treatments. *Acta Orthopedic Mexicana* 2010;24(5):324-330.
2. Higgins TF, Pittman G, Hines J *et al.* Biomechanical Analysis of distal femur fractures; fixed angle screw plate construct versus condylar blade plate. *J Orthop Trauma* 2007;21(1):43-46.
3. Sanders R. Double plating of comminuted, unstable fractures of distal femur. *JBJS* 1991;73(3):341-346.
4. Dar GN, Tak SR, Kangoo K. Comparison of outcome of distal femur fractures treated by bridge plate osteosynthesis using DCS versus supracondylar nail. *Ulus Trauma Acil Cerrahi Derg* 2009;15:148-53.
5. Huang J, Wnag Q, Gao K *et al.* Retrograde nailing versus locked plating of extra articular distal femoral fractures. *Med Princ Pract* 2013;22(2):161-166.
6. Hahn U, Helling HJ, Rehm KE *et al.* A condylar plate in distal femoral fractures. *Kongressbd Dtsch Ges Chir Kongr* 2001;118:362-366.
7. Marti A, Fankhauser C, Frenk A *et al.* Biomechanical Evaluation of LISS for the internal fixation of distal femur. *J Orthop Trauma* 2001;15(7):482-427.

## Conclusion

Distal femoral fractures accounted for 8% of the total femur fractures. These fractures pose a great challenge in treatment owing to their location, complexity and technical demand.

After evaluating 25 patients of distal femoral fractures presented to us who were treated with ORIF using LCP, we opine that standard Open Reduction Internal fixation with LCP is a very good method of treating distal femur fractures including the Muller/AO C3 variety.

We attribute the favorable results to strict adherence of principles of stabilization with rigid internal fixation and early functional rehabilitation.

LCP proved to be a good implant which could take the challenges like poor bone stock, severe comminution, both metaphyseal and articular and prove successful. So, ORIF of distal femoral fractures with LCP coupled with properly timed early and optimal rehabilitative protocol yields excellent and good results in almost all patients.

Huang J, Wang Q<sup>[5]</sup> did a retrospective study on retrograde nailing versus locked plating of extra-articular distal femur