



E-ISSN: 2395-1958
P-ISSN: 2706-6630
IJOS 2021; 7(1): 625-630
© 2021 IJOS
www.orthopaper.com
Received: 15-11-2020
Accepted: 30-12-2020

Dr. SV Shiv Sandeep
Assistant Professor, NRI
Institute of Medical Sciences,
Sangivalasa, Visakhapatnam,
Andhra Pradesh, India

Dr. Ravi Kiran Kakumanu
Associate Professor, NRI
Institute of Medical Sciences,
Sangivalasa, Visakhapatnam,
Andhra Pradesh, India

Management of fracture both bones forearm with plating/medullary nailing: A comparative study

Dr. SV Shiv Sandeep and Dr. Ravi Kiran Kakumanu

DOI: <https://doi.org/10.22271/ortho.2021.v7.i1j.2552>

Abstract

Introduction: Fracture of both bones forearm in adults occupy a large field of modern traumatology. Maintenance of radial bow, regaining length, good apposition and alignment without malrotation is essential to restore good range of motion of forearm. Aim: to compare functional and radiographic results of plate osteosynthesis to IM nailing in treatment of diaphyseal forearm fracture in adults.

Method: A prospective study comprising of 32 patients. 16 patients treated with open reduction and internal fixation using 3.5 mm DCP and 16 patients by IM nailing using 316L SS Talwarkar square nailing by closed or mini open reduction.

Result: Mean age of patients was 36.4 years (range 20 to 58 years), Maximum number of patients in this study are middle age group and mean age is 48 years most fractures were of type 22A3 as per AO/OTA classification. Average operative time was 83 minutes and 64 minutes in plating and nailing respectively. Out of 16 patients in each group in our present study we encountered complications like restriction of movements at elbow in 5 (31.25%) plating cases and 3 (18.75%) nailing cases; restriction of movements at wrist in 1(6.25%) plating case and 0 nailing cases and loss of supination or pronation or both were observed in 6 (37.5%) each in nailing and plating cases. Localised bursitis were observed in 2 (12.5) nailing cases alone & wound healing and superficial infections were observed in 2 (6.25%) plating cases alone. We had 1 (6.25%) Non-Union is case of Plating and all fractures united in cases operated with nailing. Out of the 32 sample cases, taking into the account of our functional grading we have observed that about 9 (56.25%) cases have been graded with excellent outcome in plating group and 10 (62.5%) in nailing group, similarly about 5 (31.25%) have been graded with good outcome in plating and 3 (18.75%) in nailing group respectively and satisfactory outcome in 1 (6.25%) in plating group and 3 (18.75%) in nailing group. This has been only 1 (6.25%) case which had a Poor outcome in plating group in our study.

Conclusion: We conclude that open reduction and internal fixation with dynamic compression plating is gold standard for treating diaphyseal forearm fracture in adults as it provides rigid fixation, restores forearm stability earlier and has negligible complications.

Keywords: Diaphyseal forearm fracture, dynamic compression plating, square nailing

Introduction

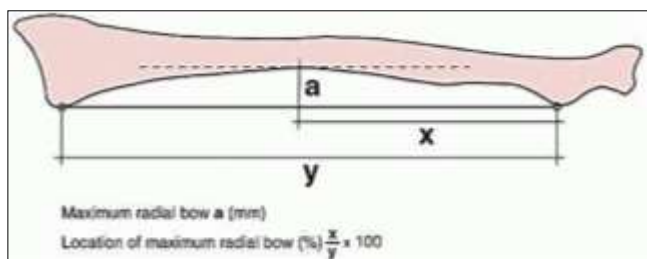
The forearm in combination of proximal and distal radio-ulnar joints, allows pronation and supination movements that are important to all of us in usual activities of daily living. Fracture of the forearm bones may result in severe loss of function unless adequately treated. Severe loss of function may result even though adequate healing of the fracture occurs. Hence a proper method of treatment is necessary to get back stability as well as normal range of function. It is difficult to achieve a satisfactory closed reduction of displaced fractures of the forearm bones and if achieved, it is hard to maintain. Unsatisfactory results of closed treatment have been reported to range from 38% to 74%. For this reason, open reduction with internal fixation is routine except for undisplaced fractures. Fractures of both bones or a displaced isolated fracture of the radius or ulna should be treated by open reduction, plate fixation and cancellous bone grafting whenever there is bone loss. This treatment is carried out as a semi-elective procedure as soon as the patient's condition warrants. Reduction is easiest when the fracture is treated within the first 48 hours. AO (Arbeitsgemeinschaft für Osteosynthesefragen)/ Association for the study of internal fixation (ASIF), dynamic and locking compression plate provides more secure fixation without cast protection.

Corresponding Author:
Dr. Ravi Kiran Kakumanu
Associate Professor, NRI
Institute of Medical Sciences,
Sangivalasa, Visakhapatnam,
Andhra Pradesh, India

It produces sufficiently rigid fixation, impaction and compression of the fracture site. It can be inserted through a smaller incision than the standard plate because no external compression device is required. Plate osteosynthesis is the most commonly used technique for the treatment of diaphyseal forearm fractures in adults. However, application of a plate can disrupt the periosteal blood supply and necessitates skin incisions that may be unsightly; there is also a risk of refracture if the implant is removed. The use of intramedullary devices to stabilize fractures is not new. Ivory pins, the Küntscher nail, the Rush nail, and Ender nails have all been in use. Nailing of the forearm, beginning with Schöne, predates nailing of the femur and tibia. Its slower technical development appears to be due to anatomic problems of the radius, the interdependence of the two bones, and the strong torque loads from pronators and supinators. In 1959, Dr. Sage used prebent triangular nails for the fixation of radius fractures with good results. In 1959, Dr. Talwarkar designed and performed fixation of both bones of forearm fractures with flexible square nails. Square nails have revolutionised the concept of internal fixation allowing a four point fixation with an adequate functional outcome. Intramedullary nailing comes with its own sets of advantages and disadvantages. The chances of infection are significantly decreased, as it is a closed procedure and uses the least amount of periosteal stripping. It also has lower refracture rates after implant removal. The present study is undertaken to provide satisfactory functional outcome in Plating and Intramedullary Nailing and compare the results considering the bony union and functional range of movements. Thirty two cases of fracture both bones forearm were selected after the inclusion and exclusion criteria, which were treated with any one of the surgical modalities described above in the department of Orthopaedics, NRIIMS and ANIL NEERUKONDA Hospital, Visakhapatnam.

Biomechanics of forearm

The ulna is a relatively straight bone, but the radius is much more complex. One frequently hears reference to the ulna moving about the radius. In fact the ulna is a relatively fixed strut around which the radius rotates in pronation and supination which points out the complexity of the angles and curves in this bone and the importance of maintaining them, especially the lateral bow of the radius fracture. If this is not done the patient may not be able to achieve full pronation and supination after fracture.



Technique for measuring the amount and location of the maximum radial bow

The maximum radial bow is determined by drawing a line from the bicipital tuberosity to the most ulnar aspect of the radius at the wrist. A perpendicular line is drawn from this line to the radius at the point of maximum radial bow, and the distance is measured in millimeters. The location of maximum radial bow is determined by dividing the distance

from the bicipital tuberosity to the point of maximum bow by the length of the entire bow. The value is expressed as a percentage. This measurement correlates with outcome following treatment of fractures of both bones of the forearm. Between the shafts of the ulna and radius is the interosseous space. The fibers of the interosseous membrane run obliquely across the interosseous space from their distal insertion on the ulna to their proximal origin on the radius. The central portion of the interosseous membrane is thickened and measures about 3.5 cm in width. Incision of the triangular fibrocartilage complex and interosseous membrane proximal to the central band decreased stability by only 11%. Incision of triangular fibrocartilage alone decreases the relative stability by 8%. Incision of the central band, however, reduced stability by 71%. The thickened central band of the interosseous membrane is a constant structure and accounts for most of the longitudinal support of the radius if the radial head is injured and requires resection.

Aims and Objectives

To compare the efficacy of nailing versus plating in the treatment of fracture both bones forearm.

Material and Methods

The study was conducted in NRI Institute of Medical Sciences, Visakhapatnam after getting clearance from the Ethics committee. All study participants gave written informed consent for participation in this study. The study was conducted from June 2017 to September 2019 on patients admitted from the emergency department or presenting in the outpatient department of the hospital. A total of 32 patients were evaluated during this period who met the inclusion and exclusion criteria.

Inclusion criteria

1. Diaphyseal fractures of both bones forearm {a3 (except a3.3);b3;c1.2;c2.
2. Age 12 years and above
3. Both males and females
4. Closed fractures
5. Segmental fractures

Exclusion criteria

1. Pathological fractures
2. Age less than 12 years
3. Severely comminuted fractures (c1.3,c2.3,c3.2,c3.3)
4. Distal 1/3 rd shaft fractures both bones forearm (a3.3)
5. Monteggia fractures
6. Galeazzi fracture
7. Multiple injuries
8. Compound fractures

Implants and surgical techniques

Method of open reduction and internal fixation

Fixation of radius

Position: Under Brachial block or general anaesthesia supine position, under the effect of tourniquet

Approach: Henry's anterior approach to all the fractures of the radius for convenience and to avoid other complications.

Incision: The length of the incision varied with the type of fracture and length of the plate used.

Site of incision: Incision is centered directly over the fracture

site to facilitate extension either proximally or distally as per the circumstances. A cleavage developed between the brachioradialis and flexor carpi radialis for Henry's approach and Extensor carpi radialis brevis

Reduction: Fragment ends are identified cleaned of hematoma and soft tissue interposition, butterfly fragments are retained with their soft tissue attachments. Fracture is anatomically reduced by fitting the butterfly fragment

Fixation of the ulna

Position: Semipronated and kept over the chest of the patient.

Incision: A long subcutaneous border of the ulna is incised centering over the fracture site.

Approach: Fracture fragments are approached by developing a cleavage between the flexor and extensor carpi ulnaris muscles.

Reduction: Reduction of the fracture and fixation of the plate is done as in the case of radius after placing a plate posteriorly. When the comminution is there the plate is fixed on the side of the comminution in order to stabilize the fragments.

Fixation: By using burns bone holder Dynamic Compression Plate is placed over the fracture site. The plate is adjusted to the center of the fracture site and the two fragments are held with BURNS forceps. A third BURNS forceps is placed over the fracture to stabilize the comminuted fragment and to prevent any angulation when the force is applied. Now, using a 7/64 drill bit the plate is fixed by inserting screws For Dynamic Compression Plate first screw is fixed on one side of the fracture with a neutral drill sleeve and second screw is then inserted on the opposite fragment after drilling through a load drill guide in an eccentric position. Remaining are in neutral position

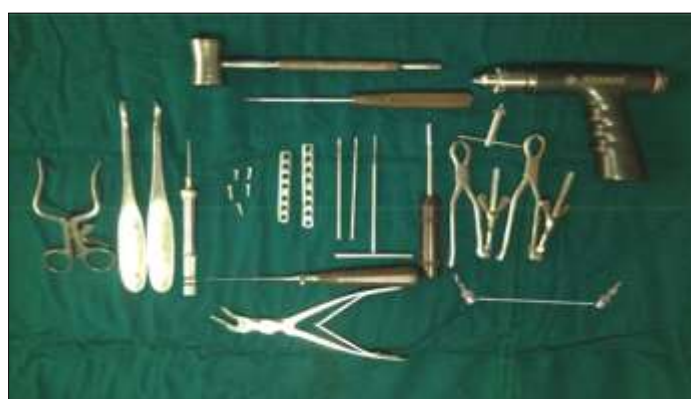

Fig 1: Instrumentation for plating forearm

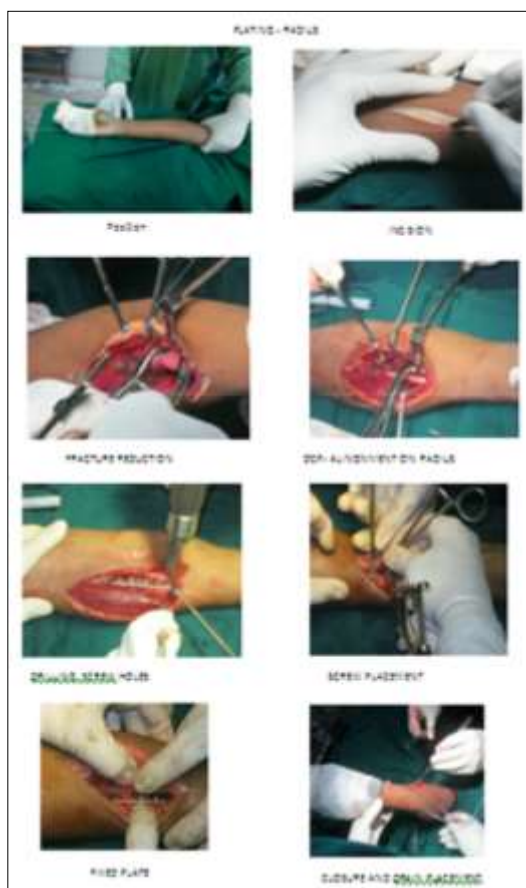


Fig 2: ORIF with DCP for radius

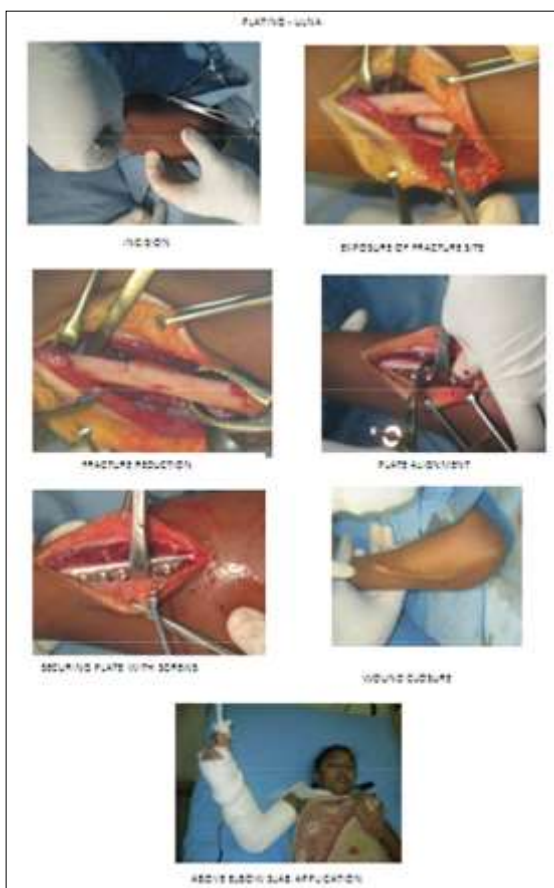

Fig 3: ORIF with DCP for ulna

Surgical technique of intramedullary nailing
Positioning of patient in intramedullary nailing

The patient in supine position with forearm rested on the side table and manipulation at fracture site was done under C-arm guidance before positioning.

Surgical technique for intramedullary nailing

Under aseptic precaution and tourniquet control, radial nail was inserted from the distal end, lateral to Lister’s tubercle. About 1-1.6 cm incision was made over the radial styloid between the abductor pollicis longus and extensor pollicis brevis tendon after holding the wrist in palmar flexion and ulnar deviation. Entry portal was made over radial styloid about 5mm from its articular surface on its lateral aspect with the help of bone awl. Bone awl inserted at 45 degree angle to the distal radius, after entering the bone for 1-1.5 cm taking care not go through the volar cortex. Angle of bone awl insertion dropped to the axis of the bone and continued for another 2-4 cm. The nail was driven from distal to proximal fragment after reducing the fracture by manual traction and manipulation at the fracture site under C-arm guidance. The

nail was driven until the tip of the nail impinges against the bone. While driving the nail it should not be rotated and wrist should be held in palmar flexion and ulnar deviation. In the final seating, the nail is in the subchondral bone at the radial head and the tail end is embedded in the cancellous bone at the styloid permitting free movements about the wrist joint.

The nail for ulna was inserted from the olecranon process at a point 5-8 mm from the dorsal cortex (to avoid entering to trochlear notch) and 5mm from the lateral cortex (to compensate for the lateral bow). An incision about 1 cm made over the end of olecranon splitting the insertion of triceps tendon. Nail was inserted into the proximal fragment after making entry portal with bone awl. Ulnar fracture was reduced by manual traction, counter traction and manipulation at the fracture site under C-arm guidance and the nail was passed. After thorough wash, gap at the fracture site was overcome by thumping at olecranon, incision was closed with interrupted silk sutures. Tourniquet was released. We applied above elbow slab in all cases and osteopenic bone.

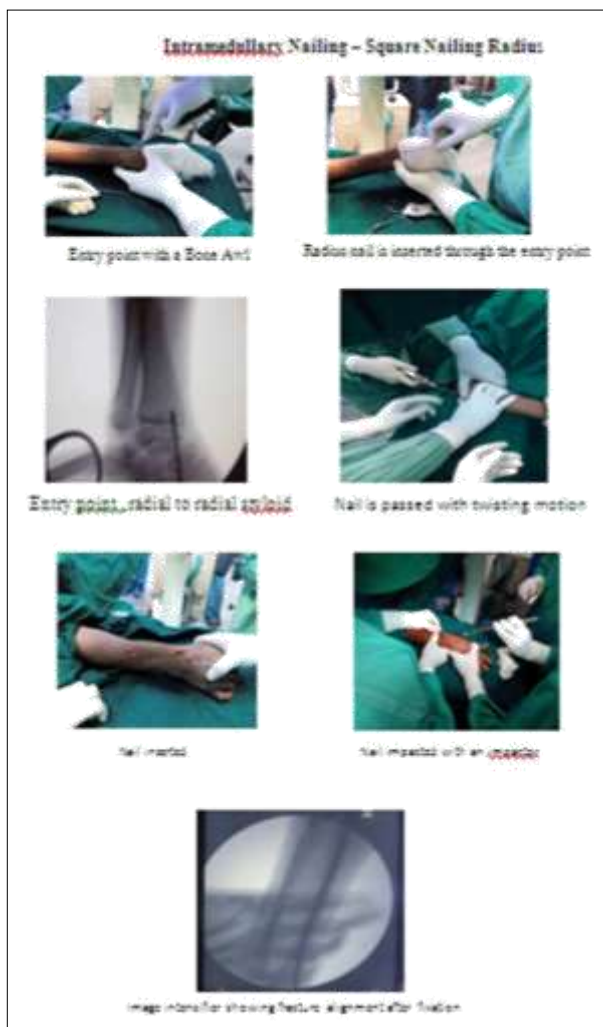

Fig 4: Intramedullary nailing – Square nailing radius



Fig 5: Intra medullary nailing (Square nails) - Ulna

Results

The present study consists of the patients admitted to orthopaedic department of NRI /ANIL NEERUKONDA Hospital between June 2017 and September 2019. A total of 1336 fracture cases were treated in Department of Orthopaedics, NRI Institute of Medical Sciences, Visakhapatnam during this period. Of these 382 were upper

limb fractures. The both bone forearm fractures were 50(13.1%). After excluding the patients who come under exclusion criteria, 32 patients were selected for detailed study. Among the 32 patients, 24(75%) were males and 8(25%) were females. The mean age of presentation was 48 years. The most common mechanism of injury was Road traffic accidents (68.75). AO OTA type A3 fracture pattern was the

most common type seen. Right sided both bone forearm fractures (18) were more compared to left (14) side. 16 cases were operated with square nailing and 16 cases were operated with Dynamic compression plating.

Age: The youngest age of patient in whom an operative procedure was performed in our series is 12 years and the oldest patient was 72 years. Maximum numbers of patients in this study are middle age group and mean age is 48 years.

Sex: In our present study forearm fractures are more in males than females

Mode of injury: Out of 32 patients, twenty two patients sustained fracture both bones forearm due to trauma, five due to fall on outstretched arm, three due to assault and two due to sports related injuries

Incidence as per site of fracture: Out of 32 patients in the present study 8 patients had proximal 1/3rd both bones shaft fractures, 22 had middle 1/3rd fractures and 2 had segmental fractures.

Incidence as per OTA classification: Out Of 32 Patients, 25 Patients Had A3 Type of Fracture, 5 Had B3 Type of Fracture and 2 Had C1.2&C2.2 Fractures.

Fracture pattern: Out of 32 patients in this present study 14 patients had transverse type of fractures, 11 had oblique type, 2 had segmental and 5 had comminution with wedge fragments.

Complications: Out of 16 patients in each group in our present study we encountered complications like restriction of movements at elbow in 5 (31.25%) plating cases and 3 (18.75%) nailing cases; restriction of movements at wrist in 1(6.25%) plating case and 0 nailing cases and loss of supination or pronation or both were observed in 6 (37.5%) each in nailing and plating cases. Localised bursitis were observed in 2 (12.5) nailing cases alone & wound healing and superficial infections were observed in 2 (6.25%) plating cases alone. We had 1 (6.25%) Non-Union is case of Plating and all fractures united in cases operated with nailing

Results: Out of the 32 sample cases, taking into the account of our functional grading we have observed that about 9 (56.25%) cases have been graded with excellent outcome in plating group and 10 (62.5%) in nailing group, similarly about 5 (31.25%) have been graded with good outcome in plating and 3 (18.75%) in nailing group respectively and satisfactory outcome in 1(6.25%) in plating group and 3 (18.75%) in nailing group. This has been only 1 (6.25%) case which had a Poor outcome in plating group in our study.

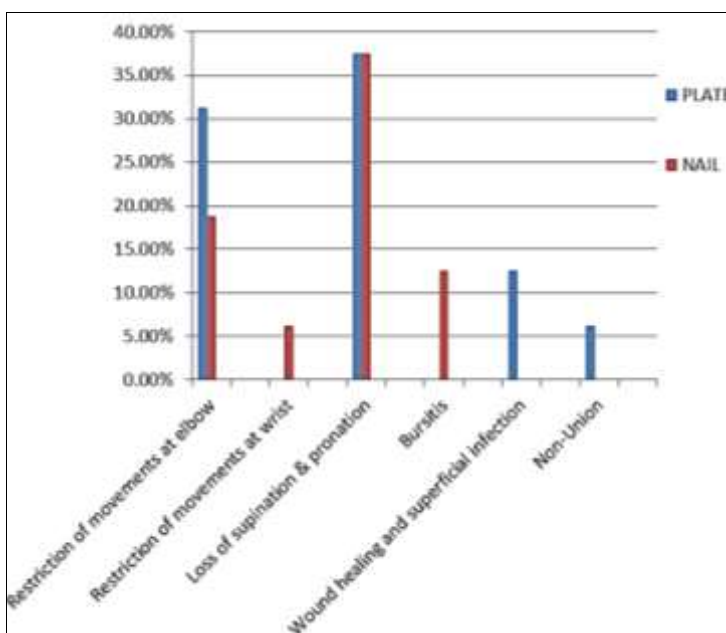


Fig 6: Incidence of complications

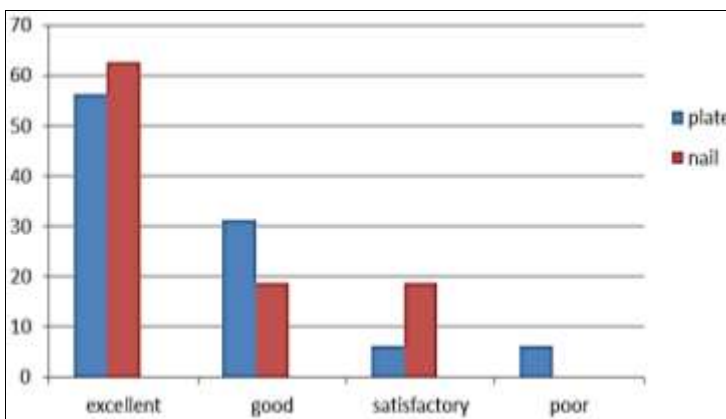


Fig 7: Results

Discussion

A functional forearm is very essential for an individual for social reasons and to his/her livelihood. Fractures of the forearm bones may result in severe loss of function unless adequately treated. The relationship of the radiohumeral, radioulnar, ulnohumeral, radiocarpal, distal radioulnar joint and the interosseous space must be perfect, otherwise some functional impairment will result. In our series, 32 patients were treated by two modalities. Open reduction and internal fixation with dynamic compression plating, closed intramedullary nailing using square nail alternately with each method. Out of 16 patient sample by each method 14 (82%) were graded excellent and good in case of plating and 13(80%) in case of nailing while plating had 1(6.25%) satisfactory or fair result as compared to 3(18.75%) in nailing. 1(6.25%) of plating cases fared poor as compared to none in nailing. We had a 93% union rate in plating as compared to 100% union rate in case of nailing. We had 1 case of nonunion in plating group, 2 cases of olecranon bursitis in nailing group and 1 case each of delayed wound healing and superficial infection in plating group. Our follow up period was between 6 months and 2 years with a mean follow up period of 1.5 years. Dana. M Street ^[6]. In his series, he has treated 137 cases of fracture both bones of forearm with square nails. He followed 103 cases out of 103 cases 86 (83.5%) cases are excellent and good, Satisfactory 8 (8%) cases and failures 9 (8.5%) cases PN Rai & RN Sharma ^[7]. In their series of 37 cases sample, they did open reduction and internal fixation, Out of 37 cases 32 (78%) cases are excellent and good; Satisfactory 4 (10%) cases and poor 1 (2%) cases. Ozkaya et Al (2009) ^[8] has published a comparative study of locked intramedullary nailing versus plating in treatment of fracture both bones forearm in 42 patients sample study with 24 patients in plating group and 20 patients in nailing group and 18 patients (%81.8) had an excellent (n=14) or good (n=4) result, 4 (%18.2) had an satisfactory/acceptable result in plating group & 18 patients (%90) had an excellent (n=16) or good (n=2) result, 2 (%10) had an satisfactory/acceptable result in nailing group. In our study we have observed that our union time for DCP plating is 12-14 weeks as compared to Anderson *et al.* Study (1975) ^[9] where union time was 7.4 weeks and Rai and Sharma observed union rate at 6-8 weeks. In our study we have observed that our union time for fractures treated with square nails was 12-14 weeks as compared to Ozkaya *et al.* series where union time was achieved in 12.8 weeks. We had a total union rate of (93.75%) in DCP plating cases as compared to Dhoan *et al.* ^[10] series where union rate was 92%. We have observed nonunion in 1 case where immobilization was inadequate and it was later operated with longer plate and bone grafting. Our Delayed union was observed in 2 cases (12.5%) as compared to 0 cases in Anderson *et al.* series & 2 cases in Rai & Sharma series. Similarly our square nailing cases had 100% union rate & no delayed union cases as compared to Dana M. Street *et al.* where there was 93% union rate and no delayed union. We had a total significant loss of (>15°) supination and pronation in forearm in 2(12.5%) cases operated with DCP and 1(6.25%) in cases operated with nailing. Ozakaya *et al.* observed an 8.8% restriction of supination and pronation and Dhoan *et al.* observed 8.8% loss of pronation and supination in their series. In our series we have observed no cases of infection in nailing group and 2 (6.25%) cases with superficial infection or wound healing problems in plating group as compared to 2.9% in Anderson *et al.* series and 5.4% in Rai and Sharma series. However we had 2 cases with olecranon

bursitis where bursae were excised and implant removed. Post removal patients were symptomless.

Summary and Conclusion

1. Fractures classified under A3, B3 group can be treated with either DCP plating or square nailing. The functional outcome did not vary when fractures united in the average time for union. In cases where there were instances of delayed union due to extended immobilisation functional deficits at wrist and elbow occurred
2. Segmental fractures united better with square nailing
3. Loss of supination and pronation of forearm was similar in both the procedures.
4. Intraoperative complications like risk of nerve injury, blood loss were reasonably less in square nailing.
5. Closed nailing has many advantages, including early union, low incidence of infection, small scars, less blood loss, and, frequently a relatively short operating time with minimal surgical trauma. Another important advantage of intramedullary implants is their stress-sharing behaviour, which facilitates secondary periosteal callus formation ^[11].
6. Square nail is associated with less post-operative infection and wound healing problems.
7. Union time varied with respect to fracture pattern and age of the patient in either of the implants. An ideal fixation with either of implants had a similar outcome.

References

1. Rush LV, Rush HL. Evolution of medullary fixation of fractures by the longitudinal pin. *Arm. J Surg* 1949;78:324-333.
2. Sage FP. Medullary fixation of forearm fractures. *J.B.J.S.* 1959;41-A:1489.
3. Talwalkar AK. Treatment of simple fracture of radius and ulna with internal fixation without external support. *Ind. J Ortho* 1967;1(1):26-30.
4. Hoppenfield S, Piet de Boer. *Surgical exposure in orthopaedics.* Jaypee brothers medical publishers 2004.
5. Texhammar R, Colton C. *AO/ASIF. Instruments and Implants.* Springer-Verlag Berlin Heidelberg 1994.
6. Street DM. Intramedullary forearm nailing. *C.O.R.R.* 1986;212:219-30.
7. Rai PK, Sharma RN. Treatment of forearm fractures by Compression plating. *Indian Journal of Orthopaedics* 1981;15(1):55-58.
8. Ozayka *et al.* Comparison between locked intramedullary nailing and plate osteosynthesis in management of adult forearm fractures *ACTA Orthopaedic and Traumatology Journal* 2009;43(1):14-20.
9. Anderson LD, David Sisk, Robert E. Compression plate fixation in acute diaphyseal fractures of the radius and ulna. *J Bone and Joint Surg* 1975;57-A(3):287-296.
10. Dhaon BK, Dhari AK, Makhani JS. Osteosynthesis in Forearm Fracture. *Indian Journal of Orthopaedics* 22(1):27-31.
11. Emil Scnemitsch H. The effect of malunion on functional outcome after plate fixation of fractures of both bones of forearm in adults. *J Bone. Joint Surg* 1992;74-A(7):1068-1078.