



## International Journal of Orthopaedics Sciences

ISSN: 2395-1958  
IJOS 2018; 4(2): 364-368  
© 2018 IJOS  
www.orthopaper.com  
Received: 19-02-2018  
Accepted: 22-03-2018

**Dr. Riyaz B Shaik**  
Associate professor, Department  
of Orthopaedics, NRI Medical  
College and Hospital,  
Chinakakani, Guntur, Andhra  
Pradesh, India

**Dr. Ashok Naidu K**  
Assistant professor, Department  
of Orthopaedics, NRI Medical  
College and Hospital,  
Chinakakani, Guntur, Andhra  
Pradesh, India

### The floating shoulder: Ipsilateral clavicular and scapular neck fractures treatment by different methods

**Dr. Riyaz B Shaik and Dr. Ashok Naidu K**

**DOI:** <https://doi.org/10.22271/ortho.2018.v4.i2f.57>

#### Abstract

**Introduction:** Double disruptions of the superior suspensory shoulder complex (SSSC) resulting in ipsilateral mid shaft clavicular and scapular body/neck fractures, are commonly referred to as a 'floating shoulder' injury. If not treated properly, this could lead to malunion, drooping shoulder deformity, shoulder pain and weakness, subacromial impingement syndrome, traumatic arthritis, and even delayed nerve and vascular damage and other complications.

**Materials and Methods:** This is a retrospective type of study of 15 cases of floating shoulder injury treated by different surgical methods. All the cases were operated electively on regular operation theatre days.

**Results:** The age range in total 15 patients was from 22 years to 62 years with mean age at the time of injury was 40.4 years. Out of 15 cases 12 (80%) were males and 3(20%) were females. High energy trauma in 12(80%) cases, fall from height in 2(13.3%) cases and fall of heavy metal object in one (6.6%) case. Associated injuries in the form of rib fractures with haemothorax in 5(33.3%) cases, head injury in 3 (20%) cases, tibial shaft fracture in one(6.6%) case and tibial spine avulsion in one (6.6%) case. Total of 7(46.6%) cases treated with only clavicle fixation, 5(33.3%) cases with both scapula and clavicle fixation and 3(20%) cases treated conservatively. Mean Herscovici score was 12.4 with excellent results in 4, good in 6, fair in 3 and poor in 2 cases.

**Conclusion:** Significant displacement at one or both fracture sites of floating shoulder injury can result in a poor functional outcome which can be improved with surgical intervention. Conservative management with acceptable results reserved for patients with minimally-displaced fractures.

**Keywords:** Superior suspensory shoulder complex, floating shoulder injury, scapula, clavicle

#### Introduction

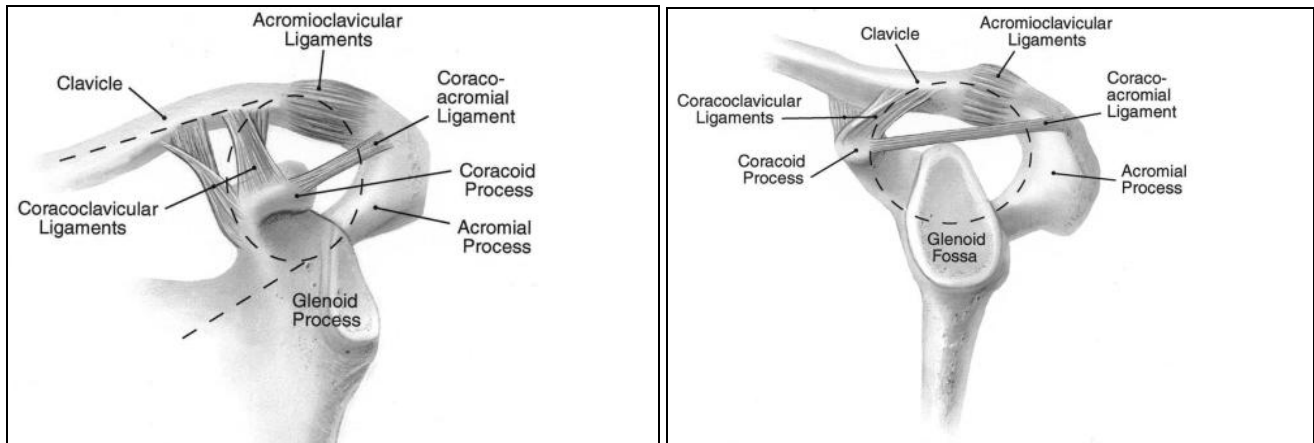
Ipsilateral midshaft clavicular and scapular body/neck fractures with double disruptions of the superior suspensory shoulder complex (SSSC) are commonly referred to as a 'floating shoulder' injury (FSI), and they result in a loss of bony attachment of the glenoid. The incidence of Floating shoulder injuries approximately 0.10% of trauma patients. It was first described by Ganz and Noesberger <sup>[1]</sup> in 1975. Subsequently, Goss <sup>[2]</sup> expanded on their definition by describing it as a 'double disruption of the superior shoulder suspensory complex. The superior shoulder suspensory complex is a bone and soft-tissue ring secured to the trunk by superior and inferior bony struts (Fig 1) from which the upper extremity is suspended. The ring is composed of the glenoid process, coracoid process, coracoclavicular ligament, distal clavicle, acromioclavicular joint, and acromial process.

The superior strut is the middle third of the clavicle, while the inferior strut is the junction of the most lateral portion of the scapular body and the most medial portion of the glenoid neck. The complex can be subdivided into three units: 1) the clavicular-acromioclavicular joint-acromial strut; 2) the three-process-scapular body junction; and 3) the clavicular-coracoclavicular ligamentous- coracoid (C-4) linkage. Secondary support is provided by the coracoacromial ligament.

When the SSSC was injured, the stability of shoulder suspension would sustain serious damage; the local muscle tension and weight of the affected limb would make the distal end of the fractured limb generate rotation and displacement forward, downward, and inward. This 3-dimensional displacement would change the start-end relationships and the structural length of the acromion and the muscles around the glenohumeral joint, resulting in a dynamic power

#### Correspondence

**Dr. Riyaz B Shaik**  
Associate professor, Department  
of Orthopaedics, NRI Medical  
College and Hospital,  
Chinakakani, Guntur, Andhra  
Pradesh, India



**Fig 1:** superior shoulder suspensory complex showing an anteroposterior view of the bony soft-tissue ring and the superior and inferior bony struts and a lateral view of the bony soft-tissue ring

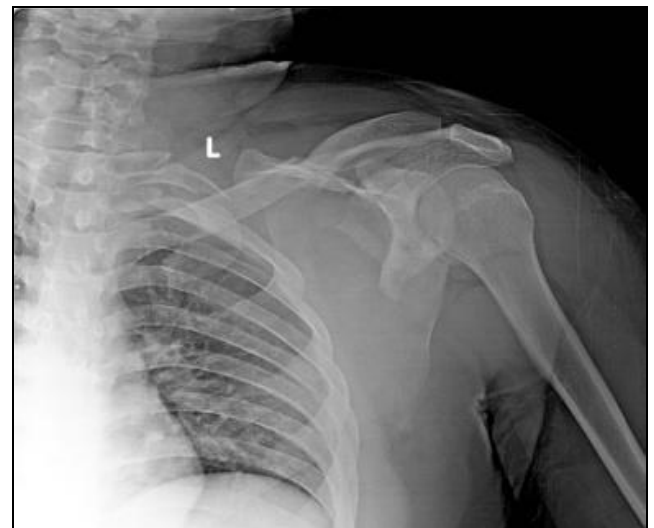imbalance of the shoulder joint. If not treated properly in the early injury period, this could lead to malunion, drooping shoulder deformity, shoulder pain and weakness, subacromial impingement syndrome, traumatic arthritis, and even delayed nerve and vascular damage and other complications. Ada and Miller<sup>3</sup> found high numbers of rotator cuff dysfunction in patients with displaced clavicular and scapular fractures, as the normal lever arm of the rotator cuff is lost with glenoid displacement. Van Noort *et al.* [4] thought that FSI was not always stable, and that if the scapula did not exhibit downward rotation and displacement, conservative treatment could achieve good results. Egol *et al.* [5] reported that surgery could not be used for routine treatment, and that each patient must undergo individualized therapy.

### Surgical Indications

In isolation, each fracture is generally minimally-displaced and can be managed non-operatively. In combination, however, each disruption can make the other unstable, for example, the glenoid neck fracture may increase the displacement of the clavicular fracture site and vice versa. The resultant instability will be greater if there is additional disruption of the clavicular-acromioclavicular joint-acromial strut or coracoacromial ligament, or if the C-4 linkage is violated. Surgical indications are displacement of a clavicular fracture by  $\geq 5$  mm; accompanying displacement of a scapular neck fracture  $\geq 10$  mm, or angular deformity  $\geq 40^\circ$ ; obvious scapular body fracture displacement or a fracture of the exterior edge of the body with penetration into the glenohumeral joint, affecting the shoulder joint; scapular neck fracture combined with glenoid cavity fracture, and articular surface exhibiting clear separation or step-like displacement  $\geq 3$  mm; coracoid fracture accompanied by coracoacromial or coracoclavicular ligament injury, with separation and displacement, or compression of blood vessels and nerves, requiring early surgical exploration; shoulder fracture subsidence  $>5$  mm, affecting the function of the rotator cuff and the motion of the inferior acromial joint; scapular spine fracture  $>5$  mm or comminuted fracture, affecting the normal sliding of anterior and inferior spine scapular muscles; GPA (gleno polar angle)  $<20^\circ$ ; other combined structural damage of the SSSC with significant displacement, and with conservative treatment expected to result in a poor outcome.

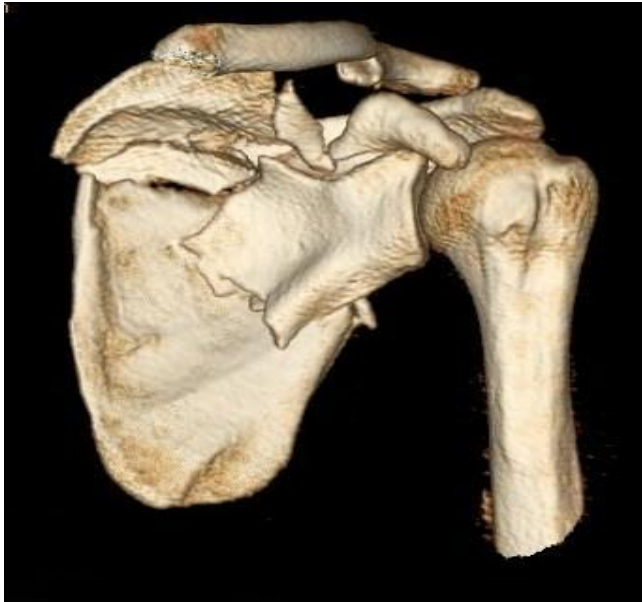### Materials and Methods

This is a retrospective type of study of 15 cases of floating shoulder injury which were admitted to NRI Medical College and Hospital, Chinakakani, Andhra Pradesh, between August 2015 to March 2017. All the patients of floating shoulder injury with age between 22 to 62 years with gross displacement at fracture site of both clavicle and scapula with medical fitness for surgery were included in the study. Patients medically unfit for surgery; those not willing for surgery and delayed presented cases were excluded from study. All the patients who attended to casualty and orthopaedic OPD examined to rule out any associated injuries. All the patients subjected for x ray of injured shoulder with clavicle (Fig), Chest x ray AP view, scapular Y view and x rays of associated limb injuries.



**Fig 2:** showing pre operative xray xray

Associated injuries like rib fractures with haemothorax and head injuries was treated by concerned specialists. All patients had computed tomography (CT) scans with three-dimensional (3D) reconstruction of the scapular fracture to assess deformity which included the glenopolar angle and medialization/lateralization (Fig.3.) of the scapular fragments.

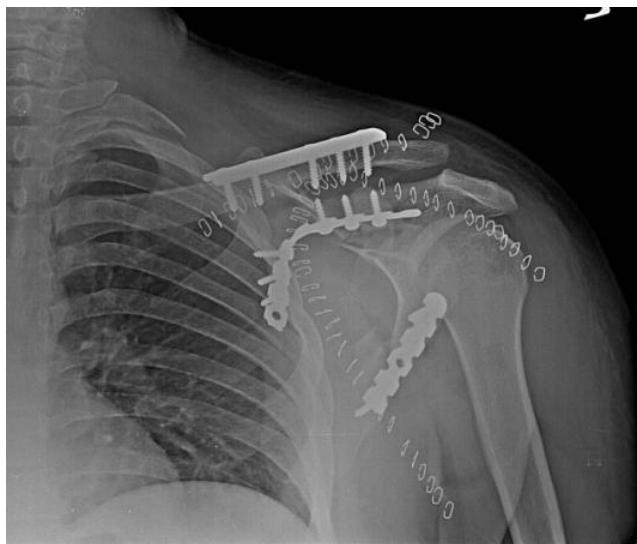

**Fig 3:** showing 3 D CT image.

After surgical profile screening patients were posted for surgery electively.

**Operative Technique**

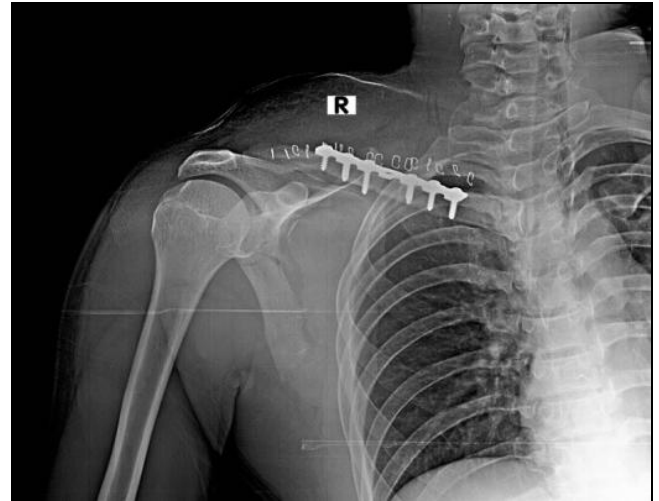
General anaesthesia was used in all 12 cases. Scrubbing and draping of injured upper limb done including shoulder upto neck region. In cases of both clavicle and scapula fixation, initially we fixed clavicle and later scapula. The clavicle approached through standard anterior approach. After subcutaneous dissection, fracture ends are freshened and fixed with adequate length of plate. After wound wash closure was done. Initial fixation of clavicle aids in indirect reduction of scapula fracture. If reduction was satisfactory we treated scapula conservatively. In cases of gross displacement of scapula fractures, we stabilized scapula with dual plating one on lateral border first followed by medial border. (Fig.4 & 5).



**Fig 4:** showing post-operative xray of both clavicle & scapula fixation

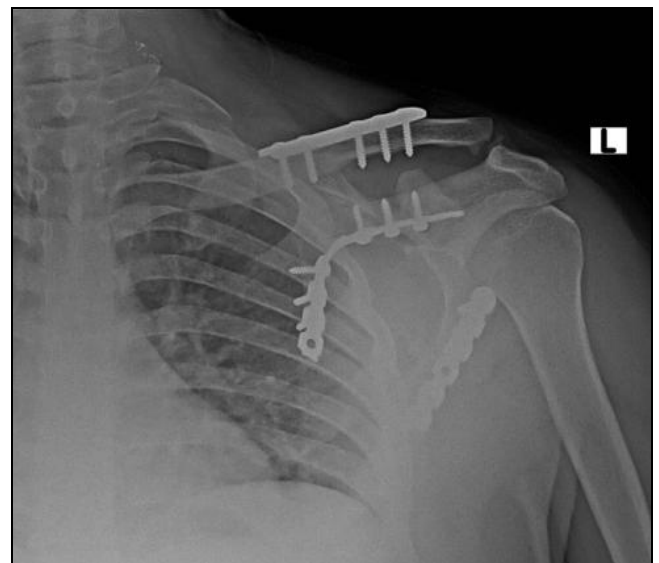
Out of five cases of both clavicle and scapula fixation, we used judet approach in two cases using curvilinear incision and in remaining three cases used two incisions one at the lateral border and another at the vertebral border. Initial fixation of lateral border helps in indirect reduction of

vertebral border. Clavicle fixed with pre contoured clavicle plate and scapula with 3.5 mm recon plates. The wound was closed in layers over negative suction drain at scapular site.



**Fig 5:** showing post-operative xray of only clavicle fixation

Post operatively patients were instructed to keep the limb elevated and move their fingers. Suction drain was removed after 48 hours. Antibiotics and analgesics were given to the patient till the time of suture removal. Sutures/staples were removed after the 10th postoperative day depending on wound condition. Shoulder immobilizer continued for four weeks and active range of movements started after four weeks. Patients were followed post operatively at 6,10 and 14 weeks thereafter every 3 months up to 1 year.(Fig.6.)



**Fig 6:** showing 4 months old post-operative xray with fracture union

At follow up detailed clinical examination was done and patients were assessed subjectively for the symptoms like pain, swelling and restriction of joint motion. Pain according to the visual analog scale (VAS) and ROM using basic clinical measurements like shoulder abduction and forward flexion were recorded. Outcomes were further measured using the Herscovici scoring system which assigns a numerical value (1-4) for pain, lifestyle, ROM, and muscle strength with a value of 16 being the best possible outcome. Return to previous work was assessed.

## Results

The age range in total 15 patients was from 22 years to 62 years with mean age at the time of injury was 40.4 years. Out of 15 cases 12 (80%) were males and 3(20%) were females. High energy trauma in 12(80%) cases, fall from height in 2(13.3%) cases and fall of heavy metal object in one (6.6%) case. Associated injuries in the form of rib fractures with haemothorax in 5(33.3%) cases, head injury in 3 (20%) cases, tibial shaft fracture in one (6.6%) case and tibial spine avulsion in one (6.6%) case. Total of 7(46.6%) cases treated with only clavicle fixation, 5(33.3%) cases with both scapula and clavicle fixation and 3(20%) cases treated conservatively. Mean Herscovici score was 12.4 with excellent results in 4, good in 6, fair in 3 and poor in 2 cases.

**Table 1:** Sex incidence

sex	Number of patients	percentage
Male	12	80%
Female	3	20%

**Table 2:** Treatment methods

Treatment methods	No. of patients	percentage
Both scapula & clavicle fixation	5	33.3%
Only clavicle fixation	7	46.6%
conservative	3	20%

**Table 3:** Mode of injury

Mode of injury	Number of patients	percentage
RTA	12	80%
Fall from height	2	13.3%
Fall of heavy object	1	6.6%

**Table 4:** Associated injuries

Associated injuries	Number of patients	percentage
Rib fractures with haemothorax	5	33.3%
Head injury	3	20%
Tibial spine avulsion	1	6.6%
Tibial shaft fracture	1	6.6%

## Discussion

Stable, minimally displaced isolated clavicular and scapular fractures heal with conservative non operative treatment. 'Floating shoulder' injuries are rare with complex fracture patterns. This type of double SSSC injury is usually the result of high-energy trauma and often has associated ipsilateral shoulder and chest trauma. If the patient can tolerate surgery, this should be the treatment. In this manner, the continuity of the SSSC can be restored, the rotation of the glenoid can be prevented, and the length and tension of the muscles around the shoulder joint and the power balance and stability of the shoulder joint can be restored. Simultaneously, good reduction and fixation can restore the normal leverage roles of the rotator cuff in the upper extremity, thus providing an anatomic and power base for the early exercise of the shoulder joint. Patients selected for conservative treatment might exhibit muscle disuse atrophy and shoulder joint adhesions if accompanied by fracture displacement, because of early exercise with an unhealed fracture. Ramsey *et al.* [6] proposed that the glenoid displacement degree might be the most important factor affecting shoulder function, and that normal anatomic structure and function of the shoulder joint should be restored through surgery. Rikli *et al.* [7] believed that unstable shoulder girdle fractures should undergo surgery for internal fixation as soon as possible, so that early functional

exercise could be performed. Type II glenoid fractures are significantly displaced, as defined by translational displacement of the glenoid fragment by 1 cm or more and/or angulatory displacement of the fragment of 40° or more in either the coronal or sagittal plane. These injuries, whether involving the surgical or anatomical neck, should at least be considered for open reduction and stabilization. Zlowodzki *et al.* [8] Performed a meta-analysis of studies of middle-third fractures of the clavicle and concluded that both displacement and comminution resulted in an increased risk of nonunion. Based upon this data, surgery should be considered for middle-third fractures of the clavicle that lack any cortical apposition and/or are severely comminuted. In a floating shoulder, the further destabilizing effect of a fracture of the glenoid neck makes operative fixation imperative. The first step in restoring the power balance and maintaining the stability of the shoulder joint was to restore the integrity and stability of the clavicle. Because of loss of clavicular bone support and suspension, the scapular neck fracture generates displacement and instability. Initial fixation of the clavicle may allow indirect reduction of the glenoid segment and obviate the need for a posterior procedure. Clavicular fracture surgery for FSI should be differentiated from simple clavicular fracture treatment, and use a plate for fixation; the fixation would thus be firm and resist rotation, and restore the supporting structures. While the Kirschner wire or Titanium elastic nail had better advantages in the fields of surgical trauma, complications and shoulder functions. Kirschner wire is unable to control rotation, and might move, become loose, exit, angulate, cause malunion and other conditions, and is not used. Some authors believe that the long-term outcomes of FSI treatment depend on the reduction quality of the scapular neck fracture; when the clavicular fracture or acromioclavicular joint dislocation obtained stable reduction, not all scapular neck fractures could indirectly achieve accurate reduction. Herscovici *et al.* [9] reported on seven patients who had excellent outcomes with a Herscovici score of 13–16 after surgical fixation of only the clavicle. Two conservatively treated patients had persistent shoulder 'drooping', but could not undergo operative treatment due to severe injuries. Yadav *et al.* [10] reported a significantly greater mean Herscovici score at 3 and 24 months in patients treated with clavicular fixation only compared to conservative management (13.9 vs 10.4 and 14.9 vs 13.0, respectively). Oh *et al.* [11] found improved clinical results in clavicular fractures treated operatively versus conservative management. Labler *et al.* [12] reported on 17 patients treated either conservatively, with clavicular fixation only, or with combined clavicular and scapular fixation. Our study includes total 15 cases with total of 7(46.6%) cases treated with only clavicle fixation, 5(33.3%) cases with both scapula and clavicle fixation and 3(20%) cases treated conservatively. Mean Herscovici score was 12.4 with excellent results in 4, good in 6, fair in 3 and poor in 2 cases comparable with other studies.

## Conclusion

Significant displacement at one or both fracture sites of floating shoulder injury can result in a poor functional outcome which can be improved with surgical intervention. Operative fixation of the clavicle alone can indirectly reduce the displaced fracture of the glenoid neck satisfactorily. However, open reduction and internal fixation of the scapula must be performed if significant displacement persists. Conservative management with acceptable results reserved for patients with minimally-displaced fractures.

## References

1. Ganz R, Noesberger B. Treatment of scapular fractures. *Hefte Unfallheilkd.* 1975; 126:59-62 (in German).
2. Goss TP. Double disruptions of the superior shoulder complex. *J Orthop Trauma.* 1993; 7:99-106.
3. Ada JR, Miller ME. Scapular fractures-analysis of 113 cases. *Clin Orthop Relat Res.* 1991; (269):174-180
4. Van Noort A, te Slaa RL, Marti PK, van der Werken C. The floating shoulder. A multicentre study. *J Bone Joint Surg (Br).* 2001; 83:795-798.
5. Egol KA, Connor PM, Karunakar MA, Sims SH, Bosse MJ, Kellam JF. The floating shoulder: clinical and functional results. *J Bone Joint Surg Am* 2001; 83-A:1188-1194.
6. Ramsey ML, Silverberg D, Iannotti JP. Ipsilateral glenoid neck and clavicular fracture: a clinical investigation. Read at the annual Meeting of the American Academy of Orthopaedic Surgeons Feb 4-8; Anaheim CA, 1997.
7. Rikli D, Regazzoni P, Renner N. The unstable shoulder girdle: early functional treatment utilizing open reduction and internal fixation. *J Orthop Trauma.* 1995; 9:93-97.
8. Zlowodzki M, Zelle BA, Cole PA. Treatment of acute midshaft clavicle fractures: systematic review of 2144 fractures. *J Orthop Trauma.* 2005; 19:504-7.
9. Herscovici D, Fiennes A, Allgower M, Ruedi TP. The floating shoulder—ipsilateral clavicle and scapular neck fractures. *J Bone Joint Surg Br.* 1992; 74:362-364
10. Yadav V, Khare G, Singh S, Kumaraswamy V, Sharma N, Rai A *et al.* A prospective study comparing conservative with operative treatment in patients with a ‘floating shoulder’ including assessment of the prognostic value of the glenopolar angle. *Bone Joint J.* 2013; 95-B:815-819
11. Oh CW, Jeon IH, Kyung HS, Park BC, Kim PT, Ihn JC. The treatment of double disruption of the superior shoulder suspensory complex. *Int Orthop.* 2002; 26:145-149
12. Labler L, Platz A, Weishaupt D, Trentz O. Clinical and functional results after floating shoulder injuries. *J Trauma-Injury Infect Crit Care.* 2004; 57:595-602