



International Journal of Orthopaedics Sciences

ISSN: 2395-1958
IJOS 2018; 4(1): 1099-1102
© 2018 IJOS
www.orthopaper.com
Received: 09-11-2017
Accepted: 12-12-2017

Dr. Sajeev KT
Resident in Orthopedics
Government Medical College,
Thrissur, Kerala, India

Dr. Bibin K Baby
Resident in Orthopedics
Government Medical College,
Thrissur, Mulamkunnathukavu,
Thrissur, Kerala, India

Dr. Jose Francis C
Professor and Head of the
Department of Orthopedics
Government Medical College,
Thrissur, Kerala, India

Clinico: Radiological outcome of diaphyseal fractures of both bone forearm in adults treated with dynamic compression plates: A prospective study

Dr. Sajeev KT, Dr. Bibin K Baby and Dr. Jose Francis C

DOI: <https://doi.org/10.22271/ortho.2018.v4.i1p.154>

Abstract

The diaphyseal fractures of radius and ulna in adults can result in significant loss of function if inadequately treated. Hence, they are usually managed by internal fixation and dynamic compression plates are the most commonly used implant for this purpose. We report the clinico-radiological outcome of both bone forearm fractures treated with Dynamic Compression Plate, through a prospective study done at Government Medical College, Thrissur from December 2014 to November 2015. The final outcome evaluated by Anderson criteria showed 62.5% excellent, 33.33% good results and only one poor outcome. Our series had 95.83% union rates with mean union duration of 13.8 weeks. We concluded that open reduction and internal fixation of adult forearm shaft fractures can be appropriately treated with Dynamic Compression Plating, which will give an excellent to good results and the results are worthy of comparison with those of the expensive newer implants.

Keywords: diaphyseal forearm fractures, Open reduction and internal fixation, dynamic compression plate, Anderson criteria

Introduction

Forearm fractures are very commonly encountered by orthopedic surgeons. Different treatment modalities were introduced from time to time and each of them had some advantage over the previous one. The forearm fractures involving radius and ulna will cause unique problems in the function of upper limb if treated inadequately. These diaphyseal fractures should be taken as articular fractures since minor deviation or malalignment in the spatial orientation of these bones can appreciably decrease the forearm functions especially the range of supination and pronation^[1, 2].

The ideal method of treating forearm shaft fractures are open reduction and internal fixation with Dynamic Compression Plate (DCP). These plates are capable of providing all basic objectives of internal fixation such as anatomical reduction, stable fixation and rapid mobilization of joints^[3]. According to a study on 129 forearm fractures fixed with DCP, done by Chapman *et al.*^[4], there was 92 % of satisfactory results with almost 90 % union rate. The dynamic compression at the fracture site will lower the incidence of delayed or nonunion.

The main drawback of DCP is that the friction at plate bone interface will result in decreased periosteal perfusion. But according to a comparative study between DCP and Locking Compression Plate (LCP) by Steven *et al.*^[5], the time to union was not affected by the type of plate used.

In our institution (Government Medical College, Thrissur), the forearm fractures are usually treated using DCP. But there were no studies available, which evaluated the functional outcome of these cases done here. So, this study was conducted to evaluate the clinico-radiological outcome of forearm shaft fractures treated with DCP in our institution.

Materials and Methods

This prospective study of 24 patients with forearm shaft fractures was done at a single centre, Department of Orthopedics, Government Medical College, Thrissur for a period of one year from December 2014 to November 2015.

Correspondence

Dr. Bibin K Baby
Resident in Orthopedics
Government Medical College,
Thrissur, Mulamkunnathukavu,
Thrissur, Kerala, India

The patients who had undergone open reduction and internal fixation with Dynamic Compression Plate for fractures of both bone forearm from our orthopedic department were selected, after obtaining necessary consents. A detailed history and clinical examinations are assessed from the case records. The consenting patients of age group 18 years to 65 years were included in the study. Those who had associated neuro vascular injuries, other fractures in the same limb, previous surgery in the fractured area, open fractures and pathological fractures were excluded from the study.

All the patients were operated in supine position under general anaesthesia or regional nerve blocks. All the fractures were approached through a Henry’s approach after applying a tourniquet with adequate pressure adjusted according to systolic pressures of the patient. The fractures were fixed with 3.5 mm DCP (6 or 7 holes) and cortical screws. A long arm splint was applied for 2-3 weeks and physiotherapy was initiated after splint removal. Heavy work and sports activities were deferred until fracture union. Follow up visits were done at 2 weeks, 4 weeks, 8 weeks and then every monthly. During each follow up clinical and radiological evaluations were done, and outcomes studied using Anderson criteria. The results were compared with other studies in the literature.

Results

A total of 24 patients with 48 forearm fractures (radius and ulna) were included in the study. The mean follow up was 5 months. In our study the age group of the patients were ranging from 18 to 60 years with mean age of 38.16 years. Our series included 18 (75 %) males and 6 (25%) females with a male to female ratio 3:1.

Table 1: Age incidence

Age group (years)	Number of cases	Percentage
18-30	8	33.33
31-40	6	25
41-50	5	20.83
51-60	5	20.83
Total	24	100

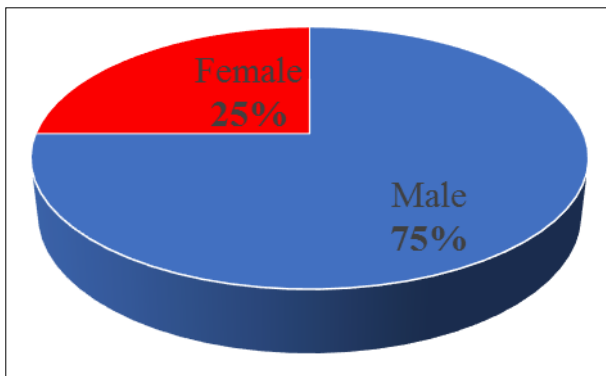


Chart 1: Sex distribution

Table 2: Comparative male to female ratio

Series	Male: Female
Talwalker ^[6]	3.2:1
Chapman ^[4]	3.5:1
Our series	3:1

In our series 62.5% cases were right sided and 37.5 % were left sided fractures. The most common mode of injury was

fall on outstretched hand followed by road traffic accidents.

Table 3: Mode of injury

Mode of Injury	Number of cases	Percentage
Fall on outstretched hand	12	50%
Assault	2	8.33%
Road traffic accident	10	41.67%

Transverse fractures were common than oblique and comminuted fractures. Most of the fractures were found in the middle third region (45.8 %). The fractures were classified according to AO system^[1].

Table 4: Fracture pattern based on AO Classification

AO type	Number of cases	Percentage
22-A-3	16	66.66
22-B-3	6	25
22-C-1	2	8.33

The functional outcomes were evaluated using Anderson *et al.* criteria^[7].

Table 5: Anderson *et al.* criteria for assessment of functional outcome

Result	Union	Flexion and Extension (wrist)	Supination and pronation
Excellent	Present	< 10° loss	<25 % loss
Good	Present	< 20° loss	<50 % loss
Fair	Present	> 20° loss	>50 % loss
Poor	Nonunion with or without loss of motion		

The fracture was considered as united, when there was evidence of periosteal callus formation bridging the fracture and trabeculations extending across the fracture line^[1,3]. The results were analyzed and evaluated accordingly. The mean duration of radiological union was found to be 13.8 weeks. The average range of motion of supination and pronation in all patients was 77° (range 55° to 85°) and 71° (range 55° to 80°), which was 90.5% and 88.75% of the contralateral rotation (mean supination 85° and pronation 80°), respectively.

Table 6: Average Duration of Radiological union of fracture

Bone involved	Time of radiological union		
	12 weeks	16 weeks	Total
Radius	13	10	23
Ulna	12	11	23
Total	25(52%)	21(44%)	46(95.83%)

Table 7: Functional outcome

Functional outcome	Anatomical results numbers (%)		Functional results numbers (%)	
Excellent	15	62.5%	15	62.5
Good	8	33.33%	7	29.17
Fair	-	-	1	4.17
Poor	1	4.17%	1	4.17
Total	24	100%	24	100

In the present study there were 2 cases of superficial infection which relieved with antibiotics and 1 case of deep infection leading to non-union of radius, which required debridement, bone grafting and refixation.

Table 8: Complications

Complications	No: of cases	
Superficial infection	2	Relieved with antibiotics
Deep infection	1	Secondary procedure done
Irritation by hardware	-	
Non-Unions	1	Infected case mentioned above
Implant failure	-	-
Tourniquet palsy/transient neuropraxia	2	Recovered

Discussion

The radius and ulna function as a single unit, they come into articulation at proximal and distal radioulnar joints and interosseous membrane spans in an oblique way between radius and ulna giving nearly 70% of forearm stability^[3]. A residual angulation of around 10° in radius or ulna can result in a loss 20° of rotations of forearm and an angulation more than 20° will be associated with functionally significant limitation of forearm rotations^[8]. Hence almost all literature advocates open reduction and internal fixation as the standard management protocol for forearm shaft fractures. Even though various locking plate models are available, DCP is still the most common plate being used for these fractures. No significant difference in fracture union rates was observed related to plate designs especially in fractures with minimum comminution^[9].

In our study majority cases (58%) were between the age group of 18 to 40 years with mean age of 38 years, which is comparable to studies by Marek *et al.*^[10] and Hidaka and Gustilo *et al.*^[11]. This shows that the incidence of forearm shaft fractures is more in younger population indicating the utmost importance of stable anatomical fixation and also need for early mobilization.

Males outnumbered the female population with a male to female ratio of M: F = 3:1 and this can be attributed to the fact in our society that the males mostly engage in outdoor activities and motorcycle accidents. The data is comparable to other studies available in literature like Chapman *et al.*^[4] and Talwalkar *et al.*^[6].

Right sided fractures (63%) were more common in our series and had no bilateral cases. The most common mode of injury is fall from height (50%). But many other studies like Marek *et al.*^[10] and Peter Kloen *et al.*^[12] showed road traffic accidents as the most common mode of injury.

3.5mm dynamic compression plate were used in all fractures, 6-hole plate was used in maximum number of fractures. Iliac crest bone graft was used in 2 cases. Postoperative plaster of paris immobilization was used for 2-4 weeks in all cases.

Out of the 46 fractures (radius and ulna) 25 fractures were united radiologically at 12 weeks, 21 fractures at 16th week with a mean duration of union 13.8 weeks. Twenty three of 24 forearms (95.83%) found united. The results of our series are in accordance with studies by Chapman *et al.*^[4] and Leung Frankie *et al.*^[13]. Excellent functional result found in 62.5% cases, satisfactory functional result in 29.17% cases, unsatisfactory in 4.1% cases and failure in 4.17% cases and data is comparable to Anderson *et al.* and Chapman *et al.* The failure was due to the deep infection and was treated with refixation after debridement. The results show that the DCP is still an excellent implant for forearm fractures. The series shows that the loss of periosteal blood supply due to bone implant interface friction is insignificant in relation to the final functional outcome. The DCP gives better anatomical reduction and stability needed for early mobilization and decreases the incidence of joint stiffness.

We encountered complications like superficial infection (2

cases), Non-union in 1 case (infected), transient neuropraxia in 2 cases. There were no implant failures or hardware irritation. The infections can be avoided by practicing strict aseptic precautions and decreasing operative time. The incidence of two cases of transient neuropraxia can be attributed to long operative time encountered in a few cases of our series and also due to difficult dissection in proximal radius resulting in transient injury to posterior interosseous nerve. The cause of persistent infection in one case of our series may be due to loss of periosteal blood supply to the bone due to DCP.

In view of the excellent and satisfactory result in 91% cases with fewer complications, Dynamic Compression Plate fixation merits continued use in case of diaphyseal fracture of radius and ulna. In our study we used six-hole DCP in most patients and in few seven holed plates were used. AO recommends the same^[1,2]. The thickness of the plate was used was 3.5mm mostly with 2.7 mm cortical screws in all the cases. It has given excellent results in management of acute diaphyseal fracture of forearm bones. The use of compression plates for acute diaphyseal fractures of the forearm is a very successful method of obtaining union and restoring optimum functional use of extremity.

With compression plate fixation, early active mobilization is possible. This helps to avoid joint stiffness and muscle atrophy, which often are responsible for unsatisfactory results. This is particularly important in view of more young population presenting with forearm shaft fractures, in whom early restoration of function is very important socially and economically. The compression plating seemed to satisfy the basic objectives of internal fixation, namely anatomical reduction, mechanically stable fixation and rapid mobilization. To conclude, dynamic compression plate is an excellent fixation for displaced diaphyseal fractures of the forearm bones. With stable/ rigid internal fixation, the external immobilization was not required in co-operative patients. This significantly alleviates the overall morbidity of the patient and decreases the economic loss caused by loss of days of work.

Conclusion

Our study has demonstrated that open reduction and internal fixation of adult forearm shaft fractures of radius and ulna can be appropriately treated with dynamic compression plating which will give an excellent to good results especially in less comminuted fractures. The complications of the DCP are negligible considering the high success rates. The fractures of both bones forearm treated by open reduction and internal fixation with DCP satisfy the basic objectives of internal fixation, anatomical reduction, mechanically stable fixation and rapid mobilization. We conclude that the results of DCP fixation are worthy of comparison with the expensive newer implants.

References

1. Bucholz RW, Charles MC, James DH, Paul T. Rockwood and Green's fractures in adults 7th ed. Lippincott. Robert

- WB, Williams & Wilkins. 2010, 882-893.
2. Canale ST, Beaty JH. Fractures of shoulder, arm, and forearm. In: Campbell's operative orthopaedics, 11th edition: Mosby, Philadelphia. 2008, 3425-3433.
 3. Nasab SAM, Sarrafan N, Arti H, Aliabadi G. Outcome of forearm shaft fractures in adults treated by open reduction and internal fixation with Dynamic Compression Plate (DCP). Pak J Med Sci. 2012; 28(1):45-48
 4. Chapman Michael W, Gordon JE, Zissimos BS, Anthony G, *et al.* Compression plate fixation of acute fractures of the diaphysis of radius and ulna. JBJS. 1989; 71-A(2):p.159-169.
 5. Stevens CT, Ten Duis HJ. Plate osteosynthesis of simple forearm fractures: LCP versus DCP plates. Acta Orthop Belg. 2008; 74(2):180-183.
 6. Talwalkar AK, Talwalkar CA. internal fixation of fractures of radius and ulna in adults with Talwalkar intramedullary nails. Indian J Orthop. 1967; 1(1):26-30
 7. Anderson LD, Sisk D, Toms RE, Park WI III. Compression plate fixation in acute diaphyseal fractures of the radius and ulna. J Bone Joint Surg [Am] 1975; 57: 287-97.
 8. Matthews LS, Kaufer H, Garver DF, Sonstegard DA. The effect on supination-pronation of angular malalignment of fractures of both bones of the forearm. J Bone Joint Surg Am. 1982; 64(1):14-17.
 9. Sushil Sharma, Harish Dang, Vivek Sharma, Siddhartha Sharma Treatment of diaphyseal forearm bone fractures by Locking Compression Plate (LCP); The Internet J Orthopedic Surgery. 2009; 11(1):1531-2968.
 10. Marek F.M. Axial Fixation of forearm fractures – J.B.J.S. 43-A, 1961; 110(1): p60-65
 11. Hidaka S, Gustilo RB. Refracture of bones of the forearm after plate removal. J Bone Joint Surg Am. 1984; 66: 1241-1243.
 12. Peter Kloen, Jim K. Wiggers, Geert A. Buijze Treatment of diaphyseal non-unions of the ulna and radius Arch Orthop Trauma Surg. 2010; 130:1439-1445.
 13. Leung Frankie, Shew-Ping Chow. A prospective, randomized trial comparing the LC-DCP with the point contact fixator for forearm fractures. JBJS. 2003; 85A(12):2343-2348.